Pharmacogn. Res., 2027; 19(2):780-790.
https://www.phcogres.com

Original Article

Preclinical Evaluation of the Gastroprotective Activity of Ethanolic Extract of *Pennisetum purpureum* in Experimental Rat Models

Prathibha B M, Kavitha SK*,Vinitha B, Shushmitha B, Yogesh HS

Department of Pharmacology, Nitte College of Pharmaceutical Sciences, Nitte (Deemed to be university) Bengaluru campus, Karnataka, INDIA.

ABSTRACT

Objectives: To evaluate the antiulcer activity of the ethanolic extract of *Pennisetum purpureum* using *in vitro, in vivo*, and molecular docking approaches. **Materials and Methods:** The whole plant was extracted by Soxhlet extraction using ethanol and analysed by preliminary phytochemical screening and HPLC. Molecular docking was performed against gastric H^+/K^+-ATPase (PDB ID: 2XZB). Acid-neutralizing activity was evaluated *in vitro*. Antiulcer activity was assessed in aspirin- and indomethacin-induced gastric ulcer models in Wistar albino rats using pantoprazole as the standard. Histopathological examination was performed to evaluate gastric mucosal protection. **Results:** Soxhlet extraction produced the highest yield (8.8%). Phytochemical analysis confirmed alkaloids, flavonoids, saponins, glycosides, steroids, and terpenoids, while HPLC identified quercetin as a major constituent. Docking showed strong binding affinity (-7.6 kcal/mol) toward gastric H^+/K^+-ATPase. The extract exhibited concentration-dependent acid-neutralizing activity, reaching 91.3% of the reference antacid at 1000 mg/mL. *In vivo*, ulcer indices were significantly reduced in both ulcer models, particularly at 400 mg/kg. Histopathology demonstrated restoration of gastric mucosal architecture with reduced inflammation. **Conclusion:** The ethanolic extract of *Pennisetum purpureum* showed significant antiulcer activity through acid-neutralizing, cytoprotective, antioxidant, and potential proton pump inhibitory mechanisms, supporting its therapeutic potential for gastric ulcer management.

Keywords: Antiulcer activity, Gastric ulcer, Histopathology, Molecular docking, *Pennisetum purpureum*, Quercetin.

Correspondence:
Dr. Kavitha S K
Department of Pharmacology, Nitte College of Pharmaceutical Sciences, Yelahanka, Bengaluru-560064, Karnataka, INDIA.
Email: kavithask175@gmail.com
ORCID: 0009-0007-5522-7201

Received: 12-08-2026;
Revised: 08-09-2026;
Accepted: 22-10-2026.

INTRODUCTION

Ulcer disease is one of the most prevalent gastrointestinal diseases around the world and will continue to be a major public health problem because of its high incidence, recurrence and complications (Anmol *et al*., 2023). It is characterised by ulcerated areas in the gastric or duodenal mucosa caused by an adverse balance between the gastroduodenal mucosal defensive mechanisms and aggressive factors (Balaky, 2024). This imbalance leads to ulceration in the gastrointestinal tract and may be caused by a number of different factors such as *Helicobacter pylori* infection, chronic usage of NSAIDs, excessive gastric acid secretion, excessive alcohol use, smoking, psychological stress and poor food choices (Roberts-Thomson, 2018). If left untreated, peptic ulcers may lead to severe complications, such as gastrointestinal bleeding, perforation, gastric outlet obstruction and, in some cases, result in life-threatening injuries or illnesses. Therefore, developing effective, safe, and affordable treatment options for ulcer management is an important focus of pharmacy research today (Srivastava *et al*., 2021).

Gastric ulcer pathogenesis is caused by many factors coming together and creating an imbalance between "aggressive" factors (hydrochloric acid, pepsin, Reactive Oxygen Species (ROS), inflammatory mediators, and bile salts; as well as (*Helicobacter pylori*) "defensive" factors (mucous membranes producing mucin; secretion of bicarbonate; the production of prostaglandins; adequate blood flow to the mucous membrane; the production of nitric oxide; and endogenous antioxidant enzymes (Syed *et al*., 2021). Oxidative stress is a major player in gastric mucosal injury by inducing lipid peroxidation, inflammation, and apoptosis (death) of cells, and disturbing the repair process of the mucosa. As a result, compounds that exhibit antioxidant activity, anti-inflammatory activity, and cytoprotective activity are expected to have a significant impact as agents for the prevention and/or treatment of gastric ulcers (Sumithira, 2025).

OPEN ACCESS

Manuscript TECHNOMEDIA

DOI: 10.5530/pres.20270289

Copyright Information :
Copyright Author (s) 2027 Distributed under Creative Commons CC-BY 4.0

Publishing Partner : Manuscript Technomedia. [www.mstechnomedia.com]

Although there are a number of classes of antiulcer medications with proven efficacy for the treatment of ulcers (e.g., proton pump inhibitors, H_2-receptor antagonists, antacids, mucosal protective agents, and antibiotics directed toward the eradication of *H. pylori*), their continued usage is often associated with unwanted side effects that are extremely limiting (e.g., headaches, diarrhea, Vitamin B_{12} deficiency, low blood Magnesium levels, rebound acid hypersecretion, drug allergies, and antibiotics leading to resistant organisms (Narayanan *et al.*, 2018). The subsequent recurrence of ulcers after stopping treatment, as well as the cost of continuous treatment with these agents present major problems. For these reasons there is a growing interest in discovering new natural agents for the treatment of gastric ulcers that have fewer side effects and more than one mechanism of gastroprotection (Bhala *et al.*, 2013).

The distinction of medicinal plants has been widespread from the earliest days of human history to the present day. As a result, they remain an integral part of ongoing drug discovery efforts. Numerous types of chemical components of plants (phytochemicals) are known to have a variety of biological effects, particularly flavonoids, phenolic compounds, tannins, alkaloids, saponins, and terpenoids. Some of these compounds possess antioxidant properties, possess anti-inflammatory properties, have antimicrobial properties, and exhibit protective effects on mucosal tissue (Narayanan *et al.*, 2018). Thus, all of these activities facilitate the process by which the conditions associated with ulcers can be resolved. As scientific studies continue to support traditional herbal medicines, many experts have turned their focus to researching the possibility of medicinal plants being used as a primary or adjunctive therapy in patients suffering from peptic ulcer disease.

Napier grass (*Pennisetum purpureum*) is a perennial grass that belongs to the Poaceae family it is grown in tropical and subtropical areas mainly as a forage crop because it grows quickly and is very productive. Different parts of the Napier grass plant have been used in traditional medicine to treat reasons for fever, wounds, inflammation, and other ailments (Monção *et al.*, 2020). There are many different types of bioactive compounds within the plant, including flavonoids, phenolic acids, alkaloids, tannins, saponins, glycosides and anthocyanins, that have antioxidant and anti-inflammatory activity. Previous pharmacological evaluations have documented the following activities of *P. purpureum*: antioxidant, antimicrobial, antihypertensive, antidiabetic, cytotoxic, and anti-inflammatory (Yang *et al.*, 2021). Therefore, it was hypothesized that the ethanolic extract of *Pennisetum purpureum* possesses significant gastroprotective activity through multiple mechanisms, including antioxidant effects, acid neutralization, cryoprotection, and inhibition of gastric H^+/K^+-ATPase. Accordingly, the present study aimed to evaluate the antiulcer potential of the ethanolic extract of *Pennisetum purpureum* using *in vitro* acid-neutralizing assays, molecular docking analysis, and *in vivo* aspirin- and indomethacin-induced gastric ulcer models, together with histopathological

MATERIALS AND METHODS

Chemicals and reagents

The generic antiulcer drug Pantoprazole, aspirin, indomethacin will be picked up at a reputable pharmaceutical provider. Standard suppliers will be used to purchase Carboxymethyl Cellulose (CMC), ethanol, and other analysis-grade reagents that will be used to make phytochemical estimations.

Experimental animals

The study will use normal Wistar (Albino) rats for the experiment. We will use a total of 20 rats (10 males and 10 females). The rat population for this study will only consist of healthy adult rats whose body weights will be limited to a maximum of 250 g and a minimum of 150 g on an average basis. They will be housed in Polycarbonate cages in a constant environmental temperature of 22°C (±2°C), with the relative humidity to be maintained between 50% and 60%, and with the light/dark cycle following a general schedule of 12 hr of light followed by 12 hr of no light. The 12-hr light/dark schedule will mimic the natural daily cycle for the rats from about 7:00 a.m. to 7:00 p.m. (lights will be off from about 7:00 p.m. to 7:00 a.m.) and will allow the rats to be fed and provided access to water on an *ad libitum* basis (the study will occur prior to the start of the regular food and water supply to the rats). Each rat will first be given a period of acclimatization prior to undergoing procedures; all procedures conducted will comply with the Guidelines of the Animal Welfare Committee (CPCSEA), and all will be conducted in accordance with the provisions of legitimate Indian Institutions Animal Rights Regulations and approved by an Institutional Animal Ethics Committee (IAEC) (Approval No. NCOPS/IAEC/14/25-26).

Collection and Authentication of Plant Material

Fresh samples (whole plants) of *Pennisetum purpureum* were collected in Bangalore, Karnataka, India and verified as authentic by the Institute for the Study of Plants (FRLHT), Bangalore, (authentication #6899), prior to use in these experiments. All collected materials were thoroughly rinsed, then dried for 30 days at room temperature in the shade. Commercial milling produced powders of dried plants for subsequent storage in sealed, moisture-proof containers. There extracted by Soxhlet extraction methods used to produce liquid extracts from *Pennisetum purpureum*: Soxhlet extraction Concentrated extracts produced by these three procedures were combined to create a

single concentrate, collected via rotary evaporation, and stored until required for further experimentation.

Phytochemical Screening

Preliminary qualitative phytochemical screening of the ethanolic extract was carried out using standard methods to identify the presence of alkaloids, flavonoids, glycosides, saponins, steroids, terpenoids and tannins (Table 1).

HPLC Analysis

HPLC assay was done to analyse the preliminary phytoconstituents on the dried sample had by HPLC grade Methanol and filtered through a 0.45 µm membrane filter and run by chromatography using reverse phase C18 Column by gradient elution using a UV/PDA detector to determine the retention time of the, thus enabling comparison between the phytoconstituents and respective reference phytoconstituent standards (Ferreres *et al.*, 2011).

Molecular Docking Studies

Molecular docking means that some kind of studies have the purpose of finding out how some selected phytoconstituents interacted with Gastric H^+/K^+-ATPase (PDB ID: 2XZB), the major target involved in the secretion of gastric acid. Then, specific molecular means of preparing the protein, performing the optimal ligand, and specific formats for performing docking were performed using standard computational protocols or methods. A variety of methods for evaluating the analysis of binding affinities and molecular interactions were all performed through the use of Biovia Discovery Studio software (Devhare and Gokhale, 2023).

In vitro Antiulcer Activity By Acid Neutralizing Capacity

Acid Neutralizing Capacity (ANC) was calculated for ethanolic extracts at four different concentrations (100 mg/mL, 200 mg/mL, 500 mg/mL, and 1000 mg/mL) using a back titration process to measure the Acid Neutralization Capacity. Each of the alcoholic extract samples were titrated with an aluminum and magnesium hydroxide solution, and the amount of hydrochloric acid neutralized by each sample was used to calculate the sample's ANC (Nwafor and Okwuasaba, 2001).

Experimental Animals

Healthy male and female Wistar albino rats, weighing 150-250 g, were used in this study. They were housed in standard laboratory conditions with *ad libitum* food and water available to them. The experimental protocols adhered to CPSC guidelines regarding animal research and were approved by the Institutional Animal Ethics Committee (IAEC) of Nitte College of Pharmacy, Bangalore (CPCSEA Approval Number: NCOPS/IAEC/14/25-26).

In vivo Antiulcer Activity

In order to evaluate the potential for healing gastroduodenal ulcers, animals were injected with acetylsalicylic acid (aspirin) and indomethacin to create experimental models of the aforementioned gastroduodenal ulcers, then tested with a total of 40 male adult Sprague-Dawley rats divided into five groups of six rats each. Each group contained one rat with a normal gastric cavity, one rat with a gastroduodenal ulcer, one rat treated with the standard drug, pantoprazole (20 mg/kg), and two rats treated with *Pennisetum purpureum* ethanolic extract (200 mg/kg and 400 mg/kg). The rats were treated with the test or control drug after they received the NSAIDs to induce ulcers. After the rats were euthanized, their stomachs were collected for gross evaluation of any ulcers that might have occurred, and the ulcer scoring indices were established using presently accepted methods of scoring ulcers (Tables 2 and 3) (Kumar, 2023).

Histopathological Examination

Samples of stomach tissue were taken, fixed in a neutral buffered formalin solution, cut into 3-µm-thick sections, embedded in paraffin, and stained with Haematoxylin/Eosin. Histopathologically, a microscope was used to evaluate the degree of mucosal injury and the protective effect of treatment, measured by the extent of damage to the mucosa post-treatment (Figure 1).

Statistical Analysis

We summarized our data by reporting means with Standard Deviations (SD's). We statistically analysed the data via one-way Analysis of Variance (ANOVA) and used SPSS version 20.0 after conducting the necessary *post hoc* tests. The criterion for determining significance was established at a p-value of <0.01.

Table 1: Phytochemical screening of pe.

Sl. No.	Phytochemical	Test description	Observation
1.	Alkaloids	Wagner's test	Brownish-red coloration
2.	Tannins	Ferric chloride test	Green Precipitate
3.	Flavonoids	Shinoda test	Red/Orange Colour
4.	Steroids	Salkowski test	Reddish - brown ring
5.	Glycosides	Keller-Kilani test	Violet/Blue/Green Colour
6.	Terpenoids	Terpenoid test	Yellow ring

RESULTS

Extraction

The yield obtained from *Pennisetum purpureum* extraction differed with the method of extraction used. Soxhlet extraction was found to yield the greatest amount (8.8%) of total bioactive components (i.e., a more effective way to extract bioactive components), which could be attributed to its ability to circulate solvents continuously and allow for better penetration of ethanol in the plant (Figure 2).

Phytochemical Tests

After conducting initial testing on plant-based chemicals that are often used as medicines, ethanol extracts of plants were found to contain multiple types of phytochemicals including alkaloids, flavonoids, saponins, glycosides, steroids, and terpenoids; however, no tannins were detected. The high number of secondary metabolites (flavonoids) present in ethanol extracts suggest that it is possible that they provided gastroprotective (antioxidant and cytoprotective) properties to the plant extract (Table 4).

HPLC

An exact replica of the chromatogram for the sample was obtained using the method described in Section 2.4. There were no other peaks present at or near the 2.380-min retention time; thus, again indicating that quercetin is the only detectable compound in the sample under the selected analytical conditions. The area percentage of this peak was found to equal 100%, indicating that quercetin represents 100% of the total sample. Furthermore, the area of this peak was recorded as 468756, confirming the presence

Table 2: Aspirin induced model.

Groups	Treatment
Group I	Normal saline
Group II	Aspirin (20 mg/kg)
Group III	Pantoprazole (20 mg/kg)
Group IV	Aspirin (on the day of experiment) + Ethanolic extract (200 mg/kg) for 5 days
Group V	Aspirin (on the day of the experiment) + Ethanolic extract (400 mg/kg)



Figure 1: Soxhlet extraction process of *Pennisetum purpureum*.

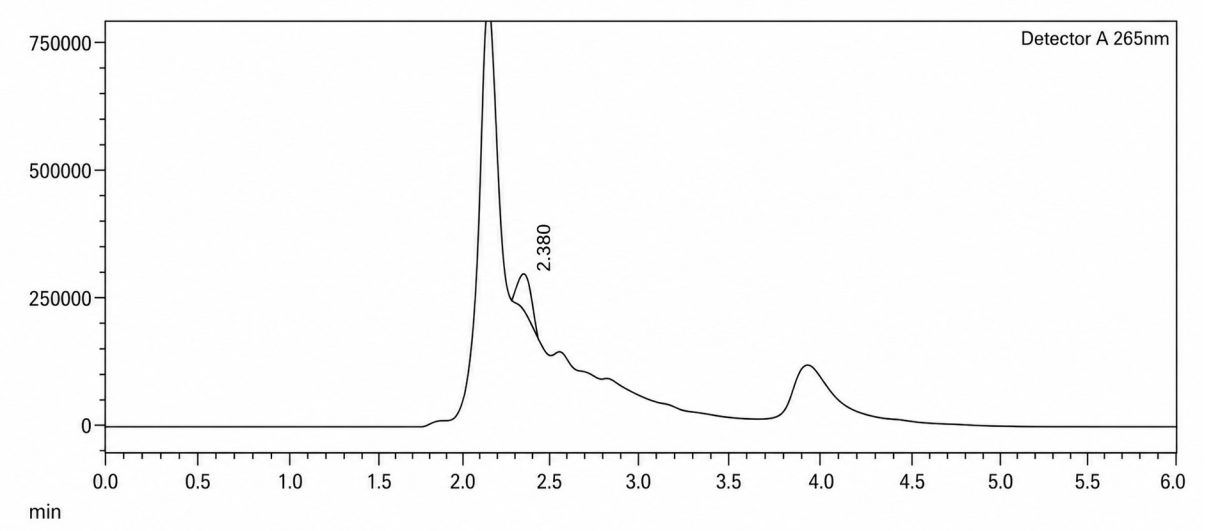

Figure 2: HPLC graph peak.

of substantial amounts of quercetin within the extract. The system suitability metrics indicate that the tailing factor is equal to 1.143, indicating that the peak is symmetrical and that the theoretical plates equal to 3226, suggesting an acceptable degree of efficiency within the column and performing separations accurately. Therefore, these results provide evidence that these methods are valid for identifying flavonoids as quercetin from plants and their extracts (Figure 3).

Molecular Docking

The molecular docking analysis indicated successful binding interactions for various phytochemicals and their respective gastric H^+/K^+-ATPases. The best-scoring binding pose of the ligand had a binding energy of -7.6 kcal/mol, which was used to indicate a stable ligand-protein complex and provide insight into a possible mechanism of inhibition of gastric acid secretion (Figures 4 and 5; Table 5).

Table 3: Indomethacin-induced model.

Groups	Treatment
Group I	Normal saline
Group II	Indomethacin (5 mg/kg)
Group III	Pantoprazole (20 mg/kg)
Group IV	Indomethacin + ethanolic extract (200 mg/kg) for 5 days
Group V	Indomethacin + Ethanolic extract (400 mg/kg) for 5 days

Table 4: Phytochemical tests.

Phytochemical	Reagent	Ethanol
Alkaloid	Wagner's test	+++
Flavonoid	H_2SO_4 test	+++
Glycoside	Killer - Kilani test	++
Saponin	Forth test	+++
Steroids	Salkowski's test	++
Tannin	Ferric chloride test	-
Terpenoids	Salkowski's test	++

Table 5: Molecular docking analysis of phytochemical of *Pennisetum purpureum* against pig Gastric H+/K+ ATPase (PDB Code 2XZB) protein.

Ligand	Binding Affinity	Rmsd /ub	Rmsd/lb
2XZB_5280863_uff_E=362.50	-7.6	0	0
2XZB_5280863_uff_E=362.50	-6.8	23.982	22.928
2XZB_5280863_uff_E=362.50	-6.8	69.127	64.875
2XZB_5280863_uff_E=362.50	-6.7	66.45	62.965
2XZB_5280863_uff_E=362.50	-6.7	71.952	68.36
2XZB_5280863_uff_E=362.50	-6.7	84.946	80.749
2XZB_5280863_uff_E=362.50	-6.6	3.405	2.889
2XZB_5280863_uff_E=362.50	-6.5	25.563	22.008
2XZB_5280863_uff_E=362.50	-6.4	60.035	56.679

Table 6: Acid Neutralizing Capacity results.

Group	Sample	Concentration	NaOH Used Trial 1Ml	NaOH Used Trial 2mL	NaOH Used Trial 3 mL	Mean NaOH Used±SD mL	ANC Value mEq
G1	PPE	100 mg/mL	43.8	44.2	43.5	43.83 ±0.35	8.08
G2	PPE	200 mg/mL	36.5	36.1	36.8	36.47± 0.35	11.77
G3	PPE	500 mg/mL	25.4	25.1	25.8	25.43 ±0.35	17.28
G4	PPE	1000 mg/mL	15.8	16.2	15.5	15.83 ±0.35	22.08
G5	Standard [AHMH]	500 mg/mL	11.6	11.9	11.4	11.63 ±0.25	24.18

In vitro

Acid neutralization ability of the extract in the acid neutralization capacity assay (Figure 3) correlates with concentration (i.e., the higher the concentration, the better the acid neutralizing ability). The most concentrated extract (1000 mg/mL) exhibited an acid neutralization capacity of 22.08 mEq, which is 91.3% of the activity of the standard antacid. This indicates a strong potential for neutralizing acid within the tested sample (Table 6 and Figure 6).

In vivo

Aspirin Induced

Ulcer ratings for There were a very large difference (p<0.001) between subjects that received the treatment and those in the control group (mean±SEM: 18.50±0.18 vs. 0.01±0.00), which strongly supports the ulcer's presence in this study. The ulceration ratings of subjects who were treated with pantoprazole (20 mg/kg) was much lower than the ulceration rating of the subjects that received no treatment (mean±SEM: 2.10±0.2000 vs. 18.50±0.1800); this indicates that pantoprazole had a protective effect against formulating an ulcer. Additionally, the ulceration

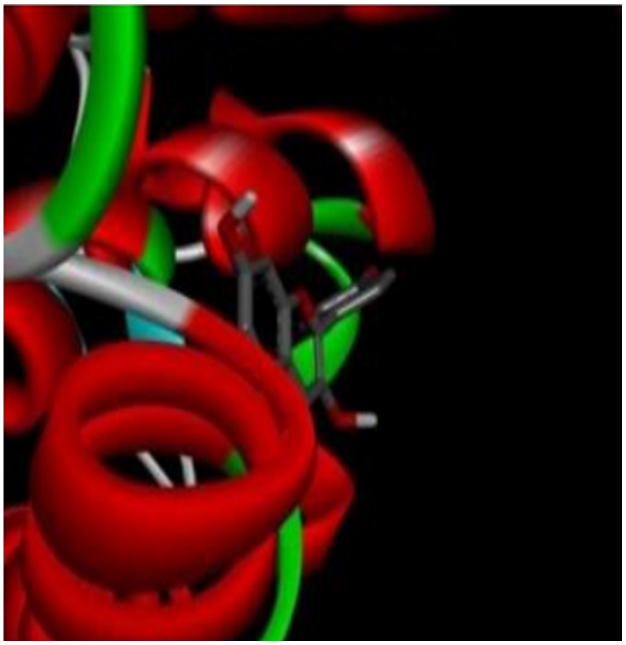

Figure 3: 3D structure of ligand-protein complex diagram.

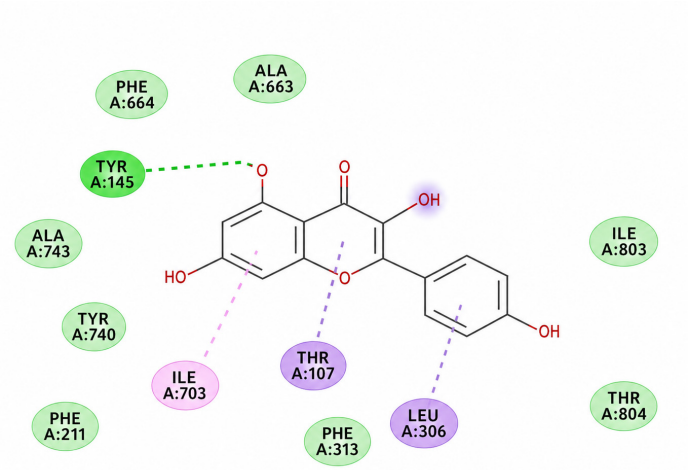

Figure 4: 2D interaction.

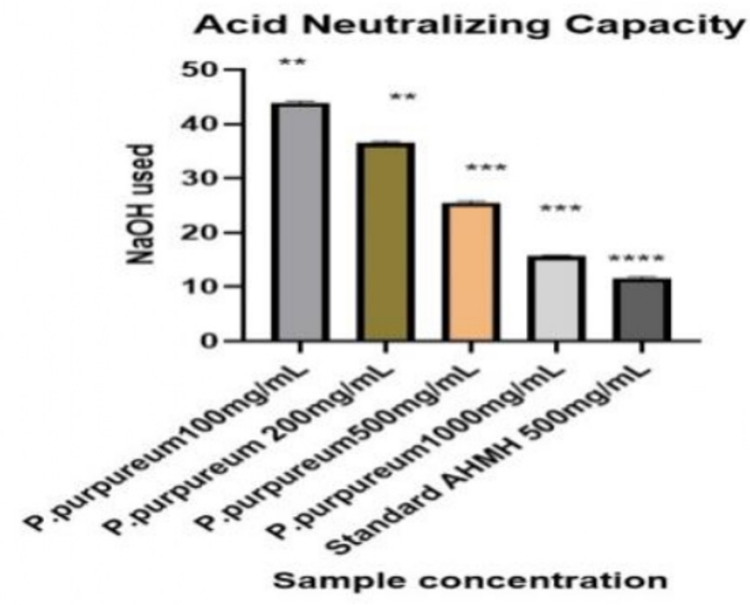

Figure 5: Acid Neutralizing Capacity.

index for both dosages of *Pennisetum purpureum* extract (200 mg/kg and 400 mg/kg) was also significantly lower, although the higher dosage was more effective. (400 mg/kg) displayed a much greater effect than the lower dosage (200 mg/kg) (mean±SEM: 11.20±0.2828 vs. 7.30±0.2366). Therefore, *Pennisetum purpureum* extract offers significant protection against gastric mucosal injury and the protection is most potent at the highest dose of *Pennisetum purpureum* extract (Figure 7).

Indomethacin Induced

There was a statistical increase in total ulcer index due to ulcer induction as shown by total ulcer index of the ulcer-induction group (20.00±0.2757) vs. the vehicle control group total ulcer index (0.03133±0.0051). Our data indicates that we successfully induced gastric ulcers through this experiment. Pantoprazole was effective at reducing total ulcer index from 20.00±0.2757 down to 3.000±0.14149 which demonstrates our ability to demonstrate strong gastroprotective effect via pantoprazole administration (20 mg/kg). Administration of *Pennisetum purpureum* at 200 mg/kg decreased the ulcer index to 12.00±0.2828, indicating moderate protection against ulceration. The 400 mg/kg dose produced a greater reduction in ulcer index (8.000±0.1414) compared to the 200 mg/kg dose, suggesting a dose-dependent antiulcer effect. The experimental animals had little variability in performance based on their low standard error of mean values. All three doses of *Pennisetum purpureum* showed some antiulcer activity but the 400 mg/kg dose appeared to provide better ulcer protection than the 200 mg/kg dose (Figure 8).

Histopathology

Aspirin-Induced Model

Histopathological evaluation of gastric tissues obtained from the aspirin ulcer test indicated marked differences between groups treated with aspirin and control (normal) groups. Control group (Normal); shows intact epithelial layer of the stomach, well-defined gastric pits, and normal architecture of the mucosa is free of any abnormalities (X40). In contrast, the ulcer control group (Aspirin); shows erosive changes in the epithelial layer of the stomach, ulcer(s), and congestion; and moderate levels of inflammatory cells infiltrating the gastric mucosa (Moderate; 3+/X40). Figure 9c of the standard-treated group showed intact epithelium and preserved mucosal morphology with no evidence of ulceration or inflammation, demonstrating effective gastroprotection (NAD+, X40). Figure 9d also demonstrated that the low-dose treated group had normal gastric epithelial cells as well as a normal-appearing mucosal architecture. There were no indications of congestion, inflammatory cell infiltrates, or ulceration. In addition, the results showed that there was a reduction in gastric injury produced by aspirin and the histological examination of the stomachs had returned to the appearance of normal stomachs (NAD+, X40). Each treated group at least had demonstrated a lot of protection, with an ulcer at the surface of the stomachs as compared to ulcers in the ulcer control group (Figure 9).

Indomethacin induced Model

The histological evaluation of the gastric tissues at a magnification of X100 showed that the normal control (Figure 9a) had a normal appearance of the gastric epithelium, glands and morphology of the mucosa. The ulcer-control tissue (Figure 9b) had evidence of ulceration of the epithelium, necrosis and inflammatory cell involvement that was moderate in severity (i.e., destructive) and had significant damage to the gastric mucosa. The standard-treated group (Figure 9c) had a preserved gastric epithelium, preserved gastric glands, and a normal-appearing mucosa with no evidence of organic, pathological findings. Figure 9d (low-dose treated group) revealed normal gastric mucosa with intact parietal cells, while Figure 9e (high-dose treated group) showed intact gastric

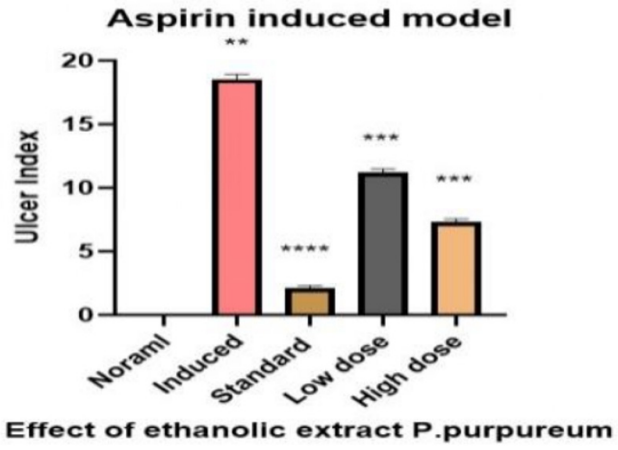

Figure 6: Aspirin induced model.

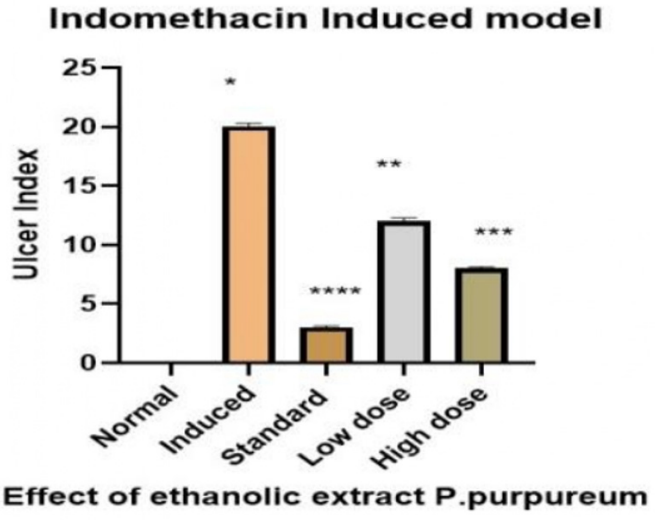

Figure 7: Indomethacin induced model.

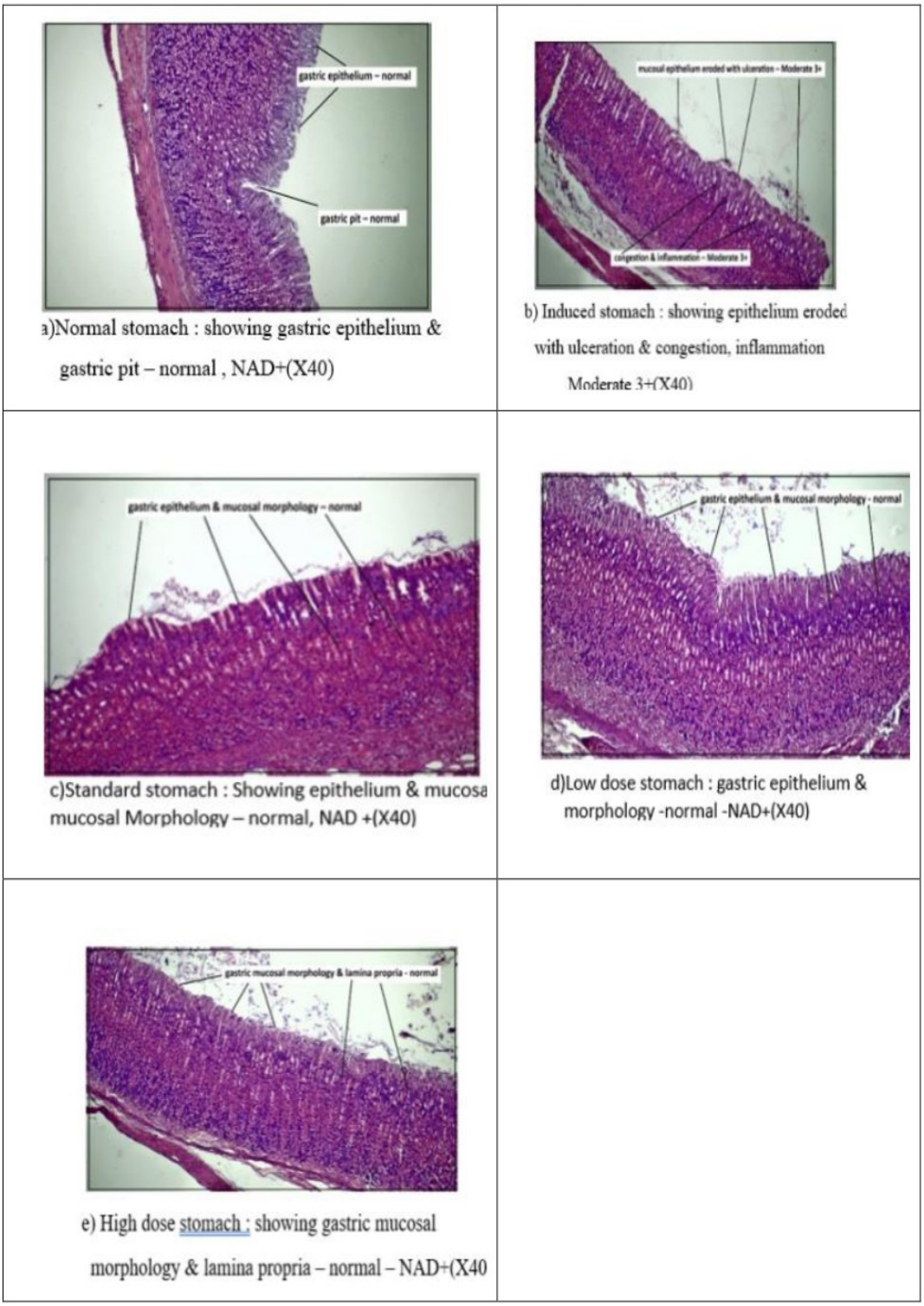

Figure 8: Histopathology of Aspirin induced model in (X40).

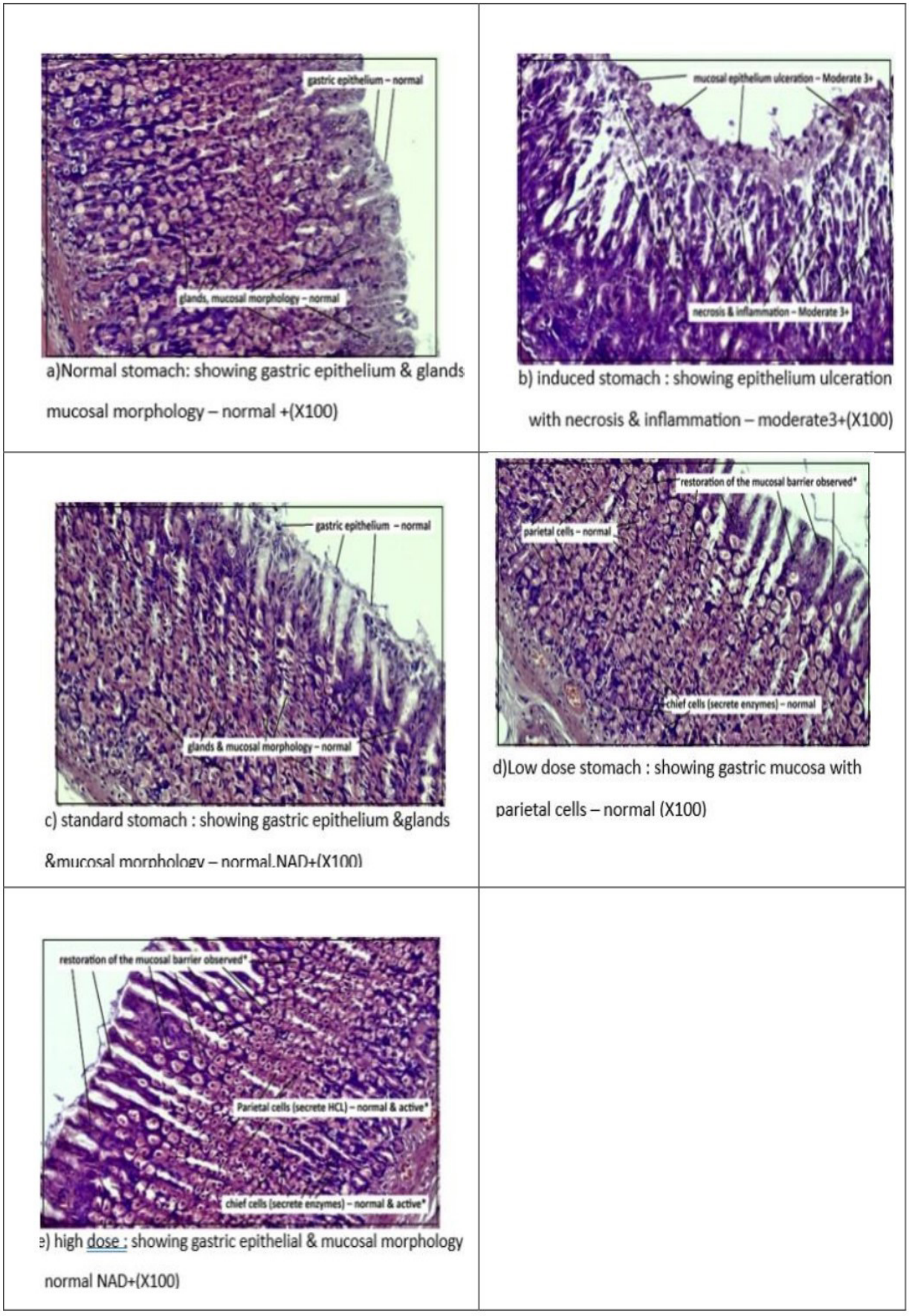

Figure 9: Histopathology of indomethacin induced model (X100).

epithelium and Normal mucosal morphology (NAD+). Overall, the treated groups demonstrated significant protection against aspirin-induced gastric ulceration, with histological features comparable to the normal control group.

DISCUSSION

Pennisetum purpureum (Poaceae) was evaluated by *in vitro, in silico*, and *in vivo* model systems to examine its potential protective effects against ulceration from epigastric ulcers. The highest yield obtained from the Soxhlet extraction method using the ethanolic extract was 8.8%. Phytochemical investigations have shown the presence of many chemically defined groups which are known to exert anti-oxidant properties and gastroprotective effects (e.g. alkaloids, flavonoids, saponins, glycosides, steroids and terpenoids). The predominant active constituent was identified as quercetin, as determined by HPLC methods of analysis. Molecular docking investigations provide evidence of significant affinity and potent interaction with Gastric H^+/K^+-ATPase (-7.6 kcal/mol), indicating a possible anti-secretory mode of action. Concentration-dependent acid neutralization activity was observed with the extract, resulting in a maximum of 91.3% activity compared to a reference antacid product at 1000 mg/mL.

Researchers have discovered using physical and histopathological methods that aspirin and indomethacin induce sores. The result of the study showed that *Pennisetum purpureum* decreases the ulcer index, enhances gastric mucosa healing and re-establish normal gastric architecture. In addition to a higher mucosal healing over time with the use of *Pennisetum purpureum*, there was also a significant reduction in the inflammatory process associated with *Pennisetum purpureum*. These results indicate that *Pennisetum purpureum* possesses significant antiulcer properties because of its antioxidant, cytoprotective, anti-secretory, and acid-neutralizing capabilities.

CONCLUSION

Recent research supports the use of the ethnomedicine, *Pennisetum purpureum*, as an alternative treatment option to conventional pharmaceuticals. Furthermore, bioactive phytochemicals found in *Pennisetum purpureum*, specifically quercetin, have exhibited significant potential as a bioactive source of alternative therapy for its use in the gastrin hydrolysis of gastric acid as well as its role in preventing the formation of dyspeptic ulcers via the restoration of the gastric mucosa. This research suggests that the pharmacological properties of *Pennisetum purpureum* are directly related to the antiulcer effects exhibited by the species as a result of its bioactive phytochemicals. Alone, the present results will continue to provide evidence supporting the traditional uses of *Pennisetum purpureum* as well as developing it into a naturally derived formulation of antiulcer products.

ACKNOWLEDGEMENT

The authors would like to thank to Dr. V. Kusum Devi, Principal of Nitte College of Pharmaceutical Sciences for providing the facilities and support to carry out this work.

ABBREVIATIONS

ANC: Acid Neutralizing Capacity; **ANOVA:** Analysis of Variance; **CMC:** Carboxymethyl Cellulose; **CPCSEA:** Committee for the Purpose of Control and Supervision of Experiments on Animals; **HPLC:** High-Performance Liquid Chromatography; **IAEC:** Institutional Animal Ethics Committee; **NSAID:** Non-Steroidal Anti-Inflammatory Drug; **PDB:** Protein Data Bank; **ROS:** Reactive Oxygen Species; **SD:** Standard Deviation; **SEM:** Standard Error of the Mean; **SPSS:** Statistical Package for the Social Sciences.

CONFLICT OF INTEREST

The authors declare that there is no conflict of interest.

AUTHORS CONTRIBUTION

Regarding the credit taxonomy, the authors contribution was **Prathibha B M:** Conceptualization, Visualization, validation, methodology, investigation, data curation, formal analysis, writing-original draft. **Dr. Kavitha S K:** Supervision, project administration writing review and editing.

ETHICAL APPROVAL STATEMENT

The study was conducted in accordance with applicable ethical guidelines and was approved by appropriate ethics committee.

REFERENCES

Anmol, S., Jaspreet, K., Meenakshi, M., & Sweta, J. (2023). Peptic ulcer disease: Retrospection on history, pathophysiology its mainstream and herbal drug therapy. *Asian Pacific Journal of Nursing and Health Sciences, 6*(2), 6-13.

Balaky, S. T. (2024). Anti *H. pylori*, anti-secretory and gastroprotective effects of *Thymus vulgaris* on ethanol-induced gastric ulcer in Sprague Dawley rats. *PLoS ONE, 19*(1), e0287569. https://doi.org/10.1371/journal.pone.0287569

Bhala, N., Emberson, J., Merhi, A., Abramson, S., Arber, N., Baron, J. A., *et al.* (2013). Vascular and upper gastrointestinal effects of non-steroidal anti-inflammatory drugs: Meta-analyses of individual participant data from randomised trials. *Lancet, 382*(9894), 769-779. https://doi.org/10.1016/S0140-6736(13)60900-9

Bhalke, R. D., Giri, M. A., Anarthe, S. J., & Pal, S. C. (2010). Antiulcer activity of the ethanol extract of leaves of *Sesbania grandiflora* (Linn.). *International Journal of Pharmacy and Pharmaceutical Sciences, 2*(4), 206-208.

Devhare, L. D., & Gokhale, N. (2023). *In silico* anti-ulcerative activity evaluation of some bioactive compound from *Cassia tora* and *Butea monosperma* through molecular docking approach. *International Journal of Pharmaceutical Sciences and Research, 14*(2), 1000-1008.

Ferreres, F., Gil-Izquierdo, A., Valentão, P., & Andrade, P. B. (2011). Structural characterization of phenolics and betacyanins in *Gomphrena globosa* by high-performance liquid chromatography-diode array detection/electrospray ionization multi-stage mass spectrometry. *Rapid Communications in Mass Spectrometry, 25*(22), 3441-3446. https://doi.org/10.1002/rcm.5251

Kumar, R. (2023). Investigation of *in vitro* method of antiulcer activity. *Journal for Research in Applied Sciences and Biotechnology, 2*(1), 264-267.

Monção, F. P., Costa, M. A., Rigueira, J. P., de Sales, E. C., Leal, D. B., da Silva, M. F., *et al.* (2020). Productivity and nutritional value of BRS capiaçu grass (*Pennisetum purpureum*)

managed at four regrowth ages in a semiarid region. *Tropical Animal Health and Production, 52*(1), 235-241. https://doi.org/10.1007/s11250-019-02015-9

Narayanan, M., Reddy, K. M., & Marsicano, E. (2018). Peptic ulcer disease and *Helicobacter pylori* infection. *Missouri Medicine, 115*(3), 219-224.

Roberts-Thomson, I. C. (2018). Rise and fall of peptic ulceration: A disease of civilization? *Journal of Gastroenterology and Hepatology, 33*(7), 1321-1326. https://doi.org/10.1111/jgh.14267

Srivastava, V., Gupta, P., & Sharma, D. (2021). Evaluation of anti-ulcer activity of methanolic extract of *Lagenaria siceraria*. *Journal of Applied Pharmaceutical Sciences and Research, 4*(2), 15-20.

Sumithira, G. (2025). *In vitro* anti-Alzheimer's potential of *Pennisetum purpureum*: Phytochemical profiling, AChE inhibition, and molecular docking analysis. *International Journal of Green Pharmacy, 19*(3).

Syed, F., Chander, R., Anitha, P., & Keerthi, B. (2021). Anti-inflammatory activity of ethanolic extract of leaves of *Agonosma cymosa* on formalin-induced paw oedema in Wistar rats. *World Journal of Pharmacy and Pharmaceutical Sciences, 7*, 1423-1430. https://doi.org/10.20959/wjpps201811-12664

Yang, S., Wang, C., Li, X., Wu, C., Liu, C., Xue, Z., & Kou, X. (2021). Investigation on the biological activity of anthocyanins and polyphenols in blueberry. *Journal of Food Science, 86*(2), 614-627. https://doi.org/10.1111/1750-3841.15598

Cite this article: Prathibha BM, Shushmitha B, Vinitha B, Kavitha SK, Yogesh HS. Preclinical Evaluation of the Gastroprotective Activity of Ethanolic Extract of *Pennisetum purpureum* in Experimental Rat Models. Pharmacog Res. 2027;19(2):780-90.