

# Oral Intake of Polyphenols of *Chromolaena odorata*: A Perspective in Peptic Ulcer, Thrombocytopenia, and Heparin-induced Bleeding Diathesis in Rodent Model

Tania S. Paul, Biswadeep B. Das<sup>1</sup>, Shakti P. Ingale<sup>2</sup>, Niruta Killedar<sup>3</sup>, Kishori G. Apte<sup>4</sup>

Satellite Lab of Venture Centre, APT Research Foundation, <sup>1</sup>Department of Genotoxicity, APT Testing and Research Pvt. Ltd., <sup>2</sup>Department of Zoology, Annasaheb Magar Mahavidyalaya, Hadapsar, <sup>3</sup>Biology Division, IISER, Pashan, <sup>4</sup>Department of Pharmacology, APT Research Foundation, Pune, Maharashtra, India

## ABSTRACT

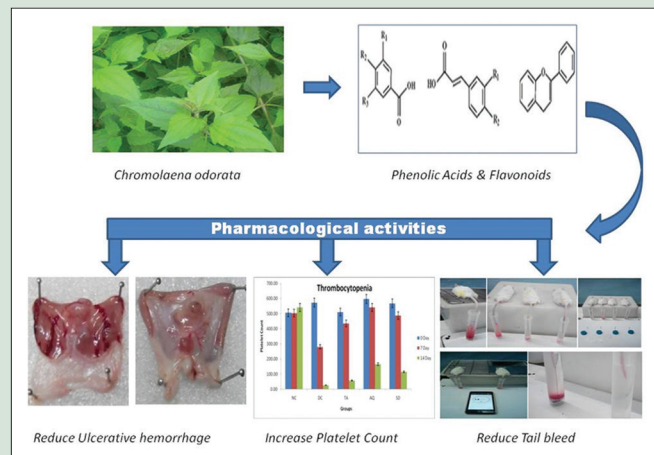
**Objective:** Bleeding disorder is of two types: external bleeding due to trauma, surgery, and internal bleeding which happens mainly due to ulcers and thrombocytopenia or use of excessive anticoagulants. Proven hemostatic activity of *Chromolaena odorata* (L) in bleeding and wound healing had encouraged to evaluate the efficacy of aqueous extract and spray-dried powder (SDP) on ulcers, thrombocytopenia, and heparin-induced bleeding diathesis. **Materials and Methods:** Internal bleeding in the form of lesions in empty stomach was induced by absolute ethanol. Busulfan is administered through intraperitoneal injection to produce thrombocytopenia in Wistar rats and heparin at 1000 IU/ml was injected intravenously to mice, and after 30 min, tail was truncated to qualitatively and quantitatively differentiate the bleeding diathesis in treated versus nontreated controls. **Results:** A significant reduction in the lesions was observed in treated rats as compared to disease control rats which was evident from ulcer index and histopathology data. Considerable protection and production of platelets were observed in the thrombocytopenia model which was drastically reduced in the Busulfan administered disease control. Both aqueous extract and SDP were successful in preventing blood loss in heparin-induced tail-bleeding model. **Conclusion:** The presence of polyphenols attributes to the crucial role of *C. odorata* in arresting internal bleeding from stomach ulcer, protecting the thrombocytes from destroying, and minimizing the bleeding diathesis in mice.

**Key words:** *Chromolaena odorata*, gastric ulcer, heparin, tail-bleeding assay, thrombocytopenia

## SUMMARY

*Chromolaena odorata* or Siam weed in spite of its traditional medicinal use, it never acquired the status of a medicinal herb. A significant reduction in the ulcers was observed in treated rats as compared to disease control rats which was evident from ulcer index and histopathology data. Considerable protection and production of platelets were observed in the thrombocytopenia model which was drastically reduced in the busulfan-administered disease control. Both aqueous extract and spray-dried powder (SDP) were successful in preventing blood loss in

heparin-induced mouse tail-bleeding model. The presence of considerable amount of flavonoids and phenols in the plant extract plays a key role in the pharmacological activities.



**Abbreviations Used:** SDP: Spray-dried powder,  $\mu$ L: Microliter, ml: Milliliter, nm: Nanometer,  $\mu$ g: Microgram, NAD: No abnormality detected, SD: Standard deviation.

## Correspondence:

Dr. Tania S. Paul,  
Satellite Lab of Venture Centre, Pune,  
Maharashtra, India.  
C/O APT Research Foundation, S. No: 36/1/1,  
M. N. 199, Vadgaon Khurd, Sinhagad Road,  
Pune - 411 041, Maharashtra, India.  
E-mail: taniapaul6@gmail.com  
**DOI:** 10.4103/pr.pr\_107\_18

## Access this article online

Website: [www.phcogres.com](http://www.phcogres.com)

## Quick Response Code:



## INTRODUCTION

Blood is one of the principal components of a body that maintains its homeostasis which many a times gets affected by factors such as disease, toxins, and drugs that may cause coagulation disorders also known as blood-clotting defects. Normally, when a person bleeds, the body starts a cascade of processes to clot the blood to prevent excessive bleeding. However, the body sometimes fails to clot the blood due to failure related to clotting factors or protein defects in the plasma. Bleeding disorders can be classified into two types which are external bleeding due to trauma, surgery,<sup>[1]</sup> etc., and internal bleeding which happens mainly due to ulcers, thrombocytopenia, or use of excessive anticoagulants. It is believed by the National Health Service, UK, that in stomach ulcers, internal bleeding is the most common complication. It can occur when an ulcer develops at the site of a blood vessel.

Due to over intake of spicy food, alcohol, meat, fish, gastric surgery, and infection by *Helicobacter pylori*, serious injury in the stomach is seen that causes gastric ulcer.<sup>[2]</sup>

Ethanol is proved to cause mucosal stasis, leading to hemorrhage and necrosis by triggering radical reactions such as lipid peroxidation.<sup>[3,4]</sup>

This is an open access journal, and articles are distributed under the terms of the Creative Commons Attribution-NonCommercial-ShareAlike 4.0 License, which allows others to remix, tweak, and build upon the work non-commercially, as long as appropriate credit is given and the new creations are licensed under the identical terms.

**For reprints contact:** [reprints@medknow.com](mailto:reprints@medknow.com)

**Cite this article as:** Paul TS, Das BB, Ingale SP, Killedar N, Apte KG. Oral intake of polyphenols of *Chromolaena odorata*: A perspective in peptic ulcer, thrombocytopenia, and heparin-induced bleeding diathesis in rodent model. Phcog Res 2018;10:426-31.

Thrombocytopenia is a body condition where the blood has too few platelets and causes mild-to-serious bleeding.<sup>[5]</sup> It is a medical term for a low platelet (thrombocytes) count of  $<150 \times 10^3/\mu\text{L}$  that plays an important role in blood clotting. It can be classified into several types depending on the factors such as immune (idiopathic) thrombocytopenic purpura, heparin-induced thrombocytopenia, thrombotic thrombocytopenic purpura, preeclampsia and hemolysis, elevated liver enzymes, and low platelet count syndrome during gestation, drug-induced thrombocytopenia, for example, quinine, infections which include hepatitis B and C, HIV, Epstein–Barr virus, *Cytomegalovirus*, parvovirus B19, varicella-zoster virus, rubella, and mumps, liver disease, and other causes such as aplastic anemia, chemotherapy, irradiation, acute leukemias, and myelodysplastic disorders may result in severe or symptomatic thrombocytopenia.<sup>[6]</sup>

In the present study, *Chromolaena odorata* R. M. King and H. Rob. (Asteraceae) (formerly known as *Eupatorium odoratum* L.) which is known for its hemostatic activity has been selected. *C. odorata* (L.) R. M. King and H. Rob. (*C. odorata*) or Siam weed is a perennial scandent or semi-woody shrub which is widely available in moderate climate as an invasive weed. Aqueous leaf extract of *C. odorata* is used as anti-inflammatory agent and membrane-stabilizing agent,<sup>[7,8]</sup> inhibits hydrated collagen lattice contraction by normal human dermal fibroblasts,<sup>[9]</sup> and decreases the bleeding time and blood volume of wounds in rats.<sup>[10]</sup> In Nigeria, the local application of the leaf extracts of *C. odorata* for sore throat and treatment of pile, burns, and wounds have been documented.<sup>[11]</sup> Isolated compound  $3\beta$ -acetyloleanolic acid from *C. odorata* showed moderate peroxisome proliferator-activated receptor-gamma agonist activity.<sup>[12]</sup> The fresh leaves of *C. odorata* or the decoction are reported for being used in the treatment of leech bites, indigestion, and skin infection.<sup>[13]</sup> The decoctions of the stems were reported to be effective against skin disease caused by *Propionibacterium acnes*.<sup>[14]</sup> Extensive literature review on *C. odorata* suggests its wound healing in experimental models.<sup>[15–17]</sup> Therefore, the hemostatic activity in external wound healing had already been justified, but scientific validation for its use in internal bleeding is not shown. Thus, the present study is put forth to evaluate the efficacy of aqueous extract and SDP of *C. odorata* on internal bleeding associated with ulcers, thrombocytopenia, and reversal of heparin-induced bleeding diathesis on laboratory animals.

## MATERIALS AND METHODS

### Chemicals and reagents

Alcohol, ranitidine, busulfan (Sigma-Aldrich), polyethylene glycol (PEG) (Sigma-Aldrich) heparin (thromboparin 1000U/ml), electronic stopwatch, disposable lancet, and nonheparinized capillary tubes are used in this study.

### Collection and authentication of plant material

The leaves of *C. odorata* (L.) R. M. King and H. Rob. were collected from Vadgaon Khurd, Pune, Maharashtra, and were authenticated by Dr. J. Jayanthi from Botanical Survey of India, Pune, under the number BSI/WRC/Cert./2014. A voucher specimen of the herbarium was submitted in APT Research Foundation, Pune.

### Preparation of plant extracts

The leaves were cleaned and shade dried in a shade dryer and the dried leaves obtained were powdered. It was then extracted in Soxhlet apparatus with Millipore RO water. The aqueous extract obtained was concentrated in rotary evaporator under vacuum and percent yield was determined.

## Preparation of spray-dried powder

Spray drying is considered as a well-established and convenient method for converting liquid materials into dry powder form. During the spray-drying process, the liquid feed is first atomized and allowed to contact with hot air which results in evaporation to yield dried particles. These particles are subsequently separated from the air stream by pressure of cyclone mixer inbuilt in spray-drying machine. Spray drying is widely used in food industries such as whey, instant coffee, milk tea, and soups as well as health-care and pharmaceuticals industries such as vitamin enzymes and bacteria.<sup>[18]</sup>

In the present study, SDP is obtained from the water extract of *C. odorata* by following the below procedure:

Briefly, the blower was started and desired inlet temperature of 150°C and outlet temperature of 80°C was set in the panel. The heater was started till the desired temperature is achieved followed by starting the compressor at 0.70 kg/cm<sup>2</sup>. Later, the feed pump was set at 14 RPM to achieve feed rate of about 750 ml/h. Initially, distilled water was fed through the feed pump and then replaced by the sample (aqueous extract of *C. odorata*). It was ensured not to have particles which might block nozzle of the atomizer. The powder obtained after spray drying was tightly packed in airtight containers for further experiments.

## Quantification of flavonoid

In brief, 1 ml of spray-dried extract (1 mg/ml) was added to 2 ml of water, and after 5 min, 3 ml of 5% sodium nitrite and 0.3 ml of 10% aluminum chloride were added. After 6 min, 2 ml of 1M sodium hydroxide was added to the solution and the volume was made up to 10 ml with distilled water. The red-colored complex formed was measured at 510 nm. The percentages of total flavonoids were calculated from the standard calibration curve of quercetin (10–250  $\mu\text{g/ml}$ ) and total flavonoids were expressed as quercetin equivalents in milligrams per gram sample.

## Quantification of phenol

The total phenolic content in the spray-dried extracts was determined with Folin–Ciocalteu (FC) reagent using gallic acid (50–250  $\mu\text{g/ml}$ ) as a standard. About 1 mg/ml of the extracts was prepared and diluted to 45 ml with distilled water in a volumetric flask. About 1 ml of FC reagent was then added and the content of the flask mixed properly. After 3 min, 3 ml of 20% sodium carbonate was added to the mixture and it was allowed to stand for 2 h with occasional shaking. The absorbance of the blue color that developed was read at 760 nm. The concentration of total phenols was expressed as gallic acid equivalents in mg/g of dry extract.

## Animal experimentation for antiulcer activity

The study was approved by the Institutional Animal Ethics Committee (IAEC) with the protocol no. RP. 04/1516 of APT Testing and Research Pvt. Ltd., Pune. The rats were divided into respective groups of six animals each.

- Group I (toxicant disease control) received absolute ethanol 99.9% (1 ml/animal)
- Group II was treated standard marketed drug (ranitidine 50 mg/kg)
- Group III was treated with aqueous extract (500 mg/kg)
- Group IV was treated with SDP (500 mg/kg).

The rats were treated with test drugs before ulceration daily for 7 days. On the day of ulceration, the rats were fasted for 24 h and then received 1 ml of absolute ethanol orally. Test drugs were administered orally 30 min before the ethanol dose on the day of ulcer induction. The animals were sacrificed by CO<sub>2</sub> exposure in CO<sub>2</sub> chamber after 1 h of ulcerogen administration, and their stomachs were excised and the gastric contents

were aspirated. The stomachs were washed with normal saline and kept in 10% formalin for the determination of ulcer index and histological studies. Ulcer index was determined by the method of de Andrade *et al.*, 2007,<sup>[19]</sup> wherein:

- Level I: Ulcer area  $\leq 1$  mm<sup>2</sup>
- Level II: Ulcer area = 1–3 mm<sup>2</sup>
- Level III: Ulcer area  $\geq 3$  mm<sup>2</sup>.

The following parameters are determined:

- Ulcerative lesion index (ULI) =  $1 \times (\text{number of ulcers in Level I}) + 2 \times (\text{number of ulcers in Level II}) + 3 \times (\text{number of ulcers in Level III})$
- Percentage protective ratio =  $100 - (\text{ULI pretreated} / \text{ULI Control}) \times 100$ .

### Chemically induced thrombocytopenia in rats

The study was approved by IAEC with the protocol no. RR 001/1415/0125 of National Toxicology Centre, Pune. Busulfan was prepared at a concentration of 100 mg/mL in PEG (Sigma) and stirred for 2 h at 20°C. This suspension was then brought to a final concentration of 10 mg/mL in PEG and stirred for 2 h at 75°C. Rats were injected intraperitoneally with busulfan on two separate occasions 3 days apart (20 mg/kg per injection). Hematology was conducted on days 0, 7, and 14 for platelet count.

### Heparin-induced bleeding time in mice

The tail-bleeding time is considered as one of the promising parameters to study hemostasis in mice.<sup>[20]</sup> This assay is simple and sensitive to the effects of heparin.<sup>[21]</sup> According to Gailani *et al.*, 2015,<sup>[22]</sup> a small truncation of the tip of the tail of mouse transects several blood vessels mainly two large lateral veins and the ventral artery. The study was approved by IAEC with the protocol no. RR 001/1415/0125 of National Toxicology Centre, Pune. Animals were anesthetized with a mixture of ketamine (24 mg/kg) and xylazine (10 mg/kg) at 1:1 ratio and administered according to body weight. Animals were placed in prone position. A distal 10-mm segment of the tail was amputated with a scalpel. The tail was immediately immersed in a 10-mL tube containing isotonic saline prewarmed in a water bath to 37°C. The position of the tail was vertical with the tip positioned about 2 cm below the body horizon. Each animal was monitored for 20 min even if bleeding ceased, to detect any re-bleeding. Bleeding time was determined using a stop clock. The experiment was terminated at the end of 20 min to avoid lethality during the experiment as required by the local animal ethics committee.

### Statistical analysis

All data were expressed as mean  $\pm$  standard error of the mean.

## RESULTS

### Effect of *Chromolaena odorata* in antiulcer activity

The untreated disease control group of animal shows  $32.33 \pm 9.27$  ulcer index, whereas the test drug-treated group shows 7.00 and 7.17 ulcer index which is comparatively low as compared to the disease control group. On the other hand, the standard drug-treated group also showed the less ulcer index, i.e.,  $11.00 \pm 7.13$  [Figure 1].

### Chemically induced thrombocytopenia in rats

After initiation of busulfan injection, the rats were found to be thrombocytopenic during the 14 days of study period. The platelet count decreased in all the groups as compared to normal control group [Figure 2].

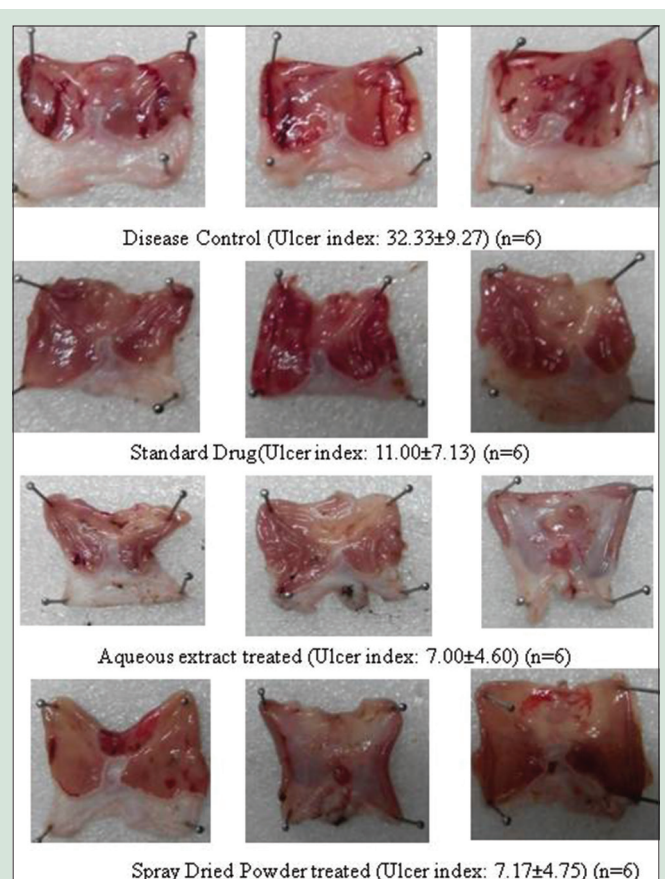


Figure 1: Lesions in the stomach of rats

### Heparin-induced clotting time in mice

The test drug-treated group showed reduction in bleeding time as compared to control group [Figure 3].

## DISCUSSION

Hemorrhages in the body can be minor or major depending on injuries and causal factors. The internal injuries are mostly unpredictable in 84% of cases.<sup>[23]</sup> Hemostasis is a natural lifesaving process in the body which helps to minimize or stop bleeding diathesis. It basically involves five major components, namely platelets, coagulation factors, coagulation inhibitors, fibrinolysis, and blood vessels.<sup>[24]</sup> Although hemostasis occurs on its own, in many situations, there is a need of the use of mechanical barriers and thermal and hemostatic drugs.<sup>[25,26]</sup> Therefore, it is believed that the variability in the severity of bleeding justifies the existence of a variety of hemostatic agent and exploration of compounds that facilitate the process is of medicinal importance.

Nowadays, in the treatment of cardiac disorders or peripheral arterial diseases, antithrombotic therapy plays a key role.<sup>[27]</sup> However, recent studies have shown that there is a risk of adverse gastric reactions in the upper gastrointestinal tract in patients taking multiple antiplatelet drugs causing hemorrhagic ulcers.<sup>[28]</sup>

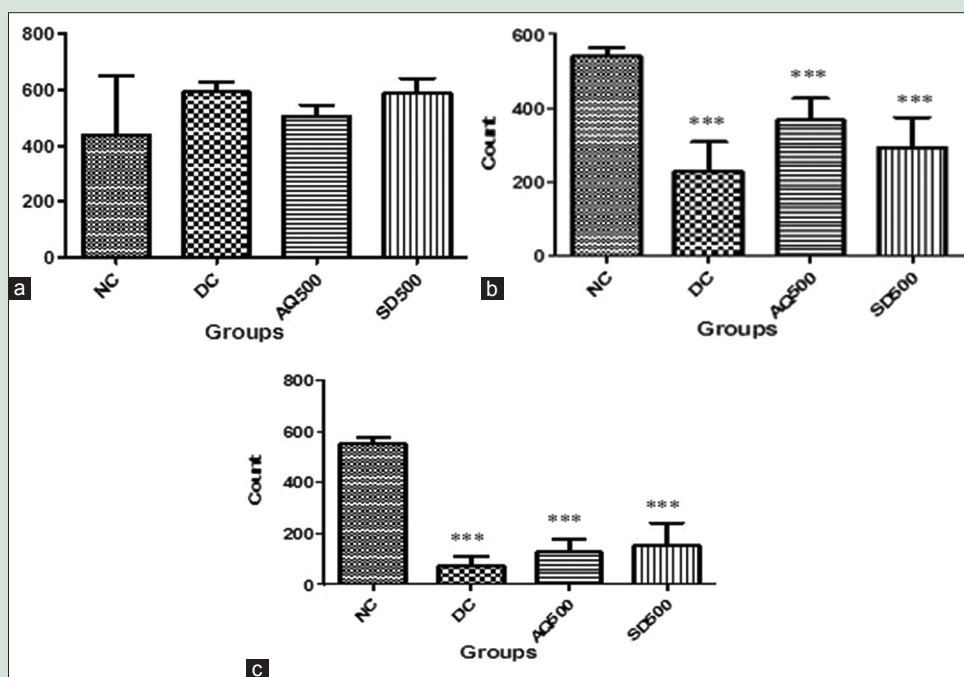
In the present study, aqueous extract of *C. odorata* was converted into SDP. The extractive percentage yield was found to be  $29.17 \pm 0.76$  (data obtained in triplicate) and spray-dried percentage yield was found to be  $8.82 \pm 2.76$  ( $n = 3$ , data obtained in triplicate). The flavonoid content was found to be  $107.88 \pm 8.08$  mg/g when compared with standard quercetin ( $R^2 = 0.995$ ) and the total phenolic content was found to be  $292.13 \pm 45.93$  mg/g of dried extract equivalent to standard gallic

acid ( $R^2 = 0.997$ ) [Table 1]. In the present study, hemorrhagic gastric ulcers were induced in rats using ethanol as oral administration of ethanol (1 ml/animal) in fasted rats induces many linear hemorrhagic ulcers 1 h after administration.<sup>[29]</sup>

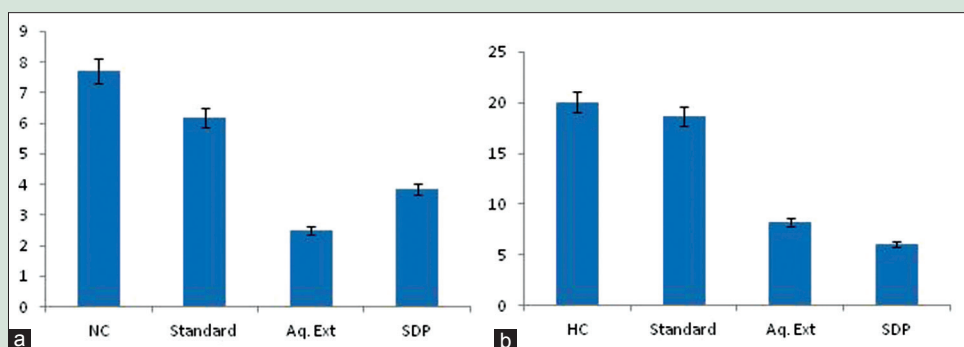
The untreated disease control group of animal shows  $32.33 \pm 9.27$  ulcer index, whereas the test drug-treated group shows  $7.00 \pm 4.60$  and  $7.17 \pm 4.75$  ulcer index which is comparatively low as compared to the disease control group. Similarly, the standard drug-treated group also showed less ulcer index, i.e.,  $11.00 \pm 7.13$ . There was a 65.98% reduction in the hemorrhage in the standard drug-treated rats as compared to the disease control. Both the aqueous extract and the SDP have reduced the hemorrhage by 78.35% and 77.82%, respectively, as compared to the disease control rats.

Histopathology observation of stomach tissue showed pathological degenerative changes in glandular stomach epithelium, mild hyperkeratosis in nonglandular stomach, and necrotic changes in the mucosa of nontreated disease control rats. Most importantly, mild-to-moderate ulceration and hemorrhages in the mucosal surface of the glandular stomach was prominent in the disease control rats. All the above parameters of histopathology evaluated was either minimal or mostly no abnormality detected in the standard drug- and *C. odorata* extract-treated groups of rats [Figure 4].

Thrombocytopenia or reduction in number of platelets is associated with bleeding which causes serious and life-threatening consequences. Nowadays, herbal medicinal products are being given importance for platelet augmentation as there are limited supportive treatments available for thrombocytopenic disorders.<sup>[30]</sup> Naturally, anemia or spontaneous



**Figure 2:** Platelet counts. (a) 0 day platelet count, (b) 7 day platelet count, (c) 14 day Platelet count

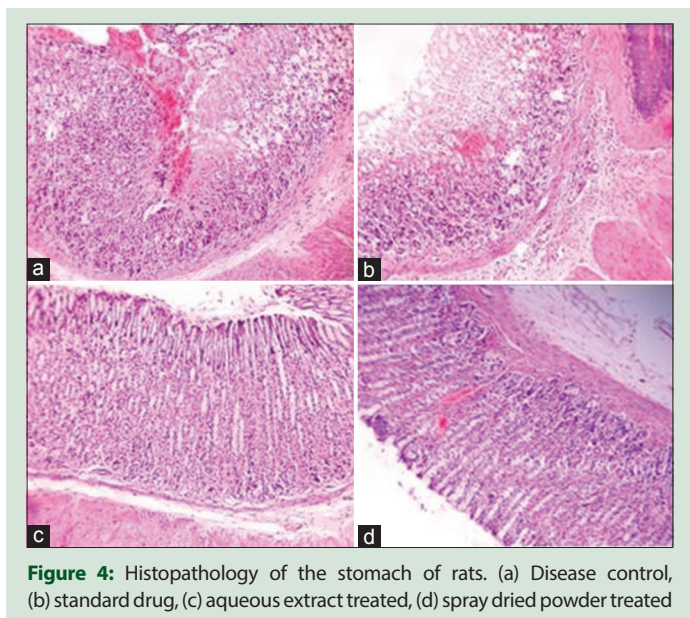


**Figure 3:** Mice tail-bleeding time. (a) Bleeding time, (b) bleeding time with heparin

**Table 1:** Extractive yield and contents of polyphenols

	Extractive percentage yield	Spray-dried percentage yield	Flavonoid content (mg/g)	Phenol content (mg/g)
<i>Chromolaena odorata</i>	29.17±0.76	8.82±2.76	107.88±8.08	292.13±45.93

Data obtained in triplicate



**Figure 4:** Histopathology of the stomach of rats. (a) Disease control, (b) standard drug, (c) aqueous extract treated, (d) spray dried powder treated

severe bleeding leads to bone marrow suppression and bone marrow being the manufacturing center of blood cells, and its suppression causes deficiency of blood cells leading to low platelet count.

Therefore, to mimic natural thrombocytopenia, busulfan, an alkylating agent, with myeloablative properties is administered through intraperitoneal injection to produce significant reduction in platelet count in Wistar rats which results in severe bleeding.<sup>[31]</sup>

In the present study, 88.09% in the platelet count was observed in disease control group on day 14 as compared to normal control rats. However, there was 76.97% reduction in platelet count in aqueous extract-treated rats as compared to normal control rats and 48.30% more than disease control rats. There was 66.16% reduction in platelet count in SDP-treated rats as compared to normal control rats and 64.81% more than disease control rats. These results indicate that oral administration of *C. odorata* extract can protect the bone marrow cells from busulfan and thereby increase the platelet count and improve thrombocytopenia condition.

Heparin confers direct effects on blood coagulation by its ability to bind and enhance the inhibitory activity of the plasma protein antithrombin against factors IIa (thrombin), Xa, and IXa which are serine proteases of the coagulation system.<sup>[32]</sup> Heparin is commonly used for the prophylaxis of venous thromboembolism and sizeable evidence suggest that heparin benefits in the treatment of cancer and other inflammatory diseases.<sup>[33]</sup>

Our aim was to observe whether the extract of *C. odorata* can reduce the bleeding diathesis when administered with and without heparin in mouse tail-bleed assay. The standard marketed drug, tranexamic acid, showed 19.58% reduction in the bleeding time of on normal mouse and 6.97% in heparin-treated mice. The aqueous extract showed 67.44% reduction in the bleeding time of on normal mouse and 58.81% in heparin-treated mice. Similarly, the SDP-treated mice showed 50.06% reduction in the bleeding time of on normal mouse and 69.77% in heparin-treated mice.

Absorbance of blood collected in saline was an indicator of blood loss; therefore, it was measured in spectrophotometer at 600 nm [Table 2]. As compared to normal control, the standard drug-treated mice showed a reduction of 31.58% in the absorbance while the aqueous extract- and SPD-treated mice showed a reduction of 59.12% and 56.14%, respectively. Whereas, after injecting heparin, the standard group showed a reduction of 16.80% in the absorbance as compared to heparin control while the aqueous extract- and SDP-treated mice showed a reduction of 68% and

**Table 2:** Absorbance of blood in saline at 600 nm

Groups	Control	Standard	Aqueous extract treated	SDP treated
Without heparin	0.570±0.100	0.390±0.080	0.233±0.055	0.250±0.020
With heparin	1.250±0.040	1.040±0.260	0.400±0.100	0.260±0.120

Data expressed as mean±SD. SD: Standard deviation; SDP: Spray-dried powder

79.20%, respectively, which indicated that blood loss was minimum in *C. odorata*-treated mice.

## CONCLUSION

It was rightly concluded by Vaisakh and Pandey, 2011,<sup>[34]</sup> in their research that *Chromolaena* or Siam weed in spite of its traditional medicinal use, it never acquired the status of a medicinal herb. Rather, it is considered as a noxious weed and tremendous efforts were always made to eradicate this so-called invasive weed. During our study, the presence of considerable flavonoid and phenol, especially tannins, indicates that the following phytochemicals might play crucial role in arresting internal bleeding from stomach ulcer, increasing the platelet count or protecting these thrombocytes from destroying, and minimizing the bleeding diathesis in heparin-induced mouse tail-bleeding model.

## Acknowledgment

The authors are thankful to Dr. Yogesh P. Talekar for double-blinded assessment of ulcer index in gastric ulcer model, Dr. Chandrashekhar Mote, MVSc., PhD (Vet Pathology), for performing the histopathology in Innovet Diagnostic Laboratory, Pune, and team of APT Research Foundation for the help and support extended.

## Financial support and sponsorship

This work was supported by Biotechnology Ignition Grant-04, BIRAC, Government of India, under Grant Number: BIRAC/VENTURE0012/BIG-04/14, for the project title: "To develop a novel, cost-effective, non-allergic herbal formulation for management of spontaneous bleeding and allied complications in Multiple Coagulation Disorders."

## Conflicts of interest

There are no conflicts of interest.

## REFERENCES

- Sauaia A, Moore FA, Moore EE, Moser KS, Brennan R, Read RA, et al. Epidemiology of trauma deaths: A reassessment. *J Trauma* 1995;38:185-93.
- Mhaskar RS, Ricardo I, Azliyati A, Laxminarayan R, Amol B, Santosh W, et al. Assessment of risk factors of *helicobacter pylori* infection and peptic ulcer disease. *J Glob Infect Dis* 2013;5:60-7.
- Shah PJ, Gandhi MS, Shah MB, Goswami SS, Santani D. Study of *Mimusops elengi* bark in experimental gastric ulcers. *J Ethnopharmacol* 2003;89:305-11.
- Raffin RP, Colomé LM, Schapoval EE, Jornada DS, Pohlmann AR, Guterres SS. Gastro-resistant microparticles containing sodium pantoprazole: Stability and *in vivo* anti-ulcer activity. *Open Drug Deliv J* 2007;1:28-35.
- Bhavya R, Jyothi Y, Rabbani SI. Potential benefits of *Boerhavia diffusa* leaves extract for the management of thrombocytopenia in sprague dawley rats. *Res J Pharm Biol Chem Sci* 2015;6:925-8.
- Gauer RL, Braun MM. Thrombocytopenia. *Am Fam Physician* 2012;85:612-22.
- Owoyele VB, Adediji JO, Soladoye AO. Anti-inflammatory activity of aqueous leaf extract of *Chromolaena odorata*. *Inflammopharmacology* 2005;13:479-84.
- Umukoro S, Ashrobi RB. Evaluation of anti-inflammatory and membrane stabilizing effects of *Eupatorium odoratum*. *Int J Pharmacol* 2006;2:509-12.
- Phan TT, Hughes MA, Cherry GW, Le TT, Pham HM. An aqueous extract of the leaves of *Chromolaena odorata* (formerly *Eupatorium odoratum*) (Eupolin) inhibits hydrated collagen lattice contraction by normal human dermal

- fibroblasts. *J Altern Complement Med* 1996;2:335-43.
10. Pandith H, Thongpraditchote S, Wongkrajang Y, Gritsanapan W. *In vivo* and *in vitro* hemostatic activity of *Chromolaena odorata* leaf extract. *Pharm Biol* 2012;50:1073-7.
  11. Kigigha LT, Zige DV. Activity of *Chromolaena odorata* on enteric and superficial etiologic bacterial agents. *Am J Res Commun* 2013;1:266-76.
  12. Zhang ML, Irwin D, Li XN, Sauriol F, Shi XW, Wang YF, *et al*. PPAR $\gamma$  agonist from *Chromolaena odorata*. *J Nat Prod* 2012;75:2076-81.
  13. Panyaphu K, On TV, Sirisa-ard P, Srisa-nga P, ChansaKaow S, Nathakarnkitkul S, *et al*. Medicinal plants of the mien (Yao) in Northern Thailand and their potential value in the primary healthcare of postpartum women. *J Ethnopharmacol* 2011;135:226-37.
  14. Pandurangan A, Kavita R, Apoovra S. Evaluation of antimicrobial and antihelminthic activity of leaves of *Chromolaena odorata*. *Int Bull Drug Res* 2015;5:64-71.
  15. Mahmood AA, Indran M, Salmah I, Sidix K, Suzainur KA. Evaluation of *in vivo* wound healing activity of *Chromolaena odorata* leaf extract on excision wounds model in rats. *J Food Technol* 2005;3:126-9.
  16. Anyasor GN, Aina DA, Olushola M, Aniyikawe AF. Phytochemical constituents, proximate analysis, antioxidants, anti-bacterial and wound healing properties of leaf extracts of *Chromolaena odorata*. *Ann Biol Res* 2011;2:441-51.
  17. Vijayaraghavan K, Rajkumar J, Seyed MA. Efficacy of *Chromolaena odorata* leaf extracts for the healing of rat excision wounds. *Vet Med* 2017;62:565-78.
  18. Anandharamkrishnan C, Rielly CD, Stapley AG. Effects of process variables on the denaturation of whey proteins during spray drying. *Drying Technol* 2007;25:799-7.
  19. de Andrade SF, Lemos M, Comunello E, Noldin VF, Filho VC, Niero R, *et al*. Evaluation of the antiulcerogenic activity of *Maytenus robusta* (Celastraceae) in different experimental ulcer models. *J Ethnopharmacol* 2007;113:252-7.
  20. Liu Y, Jennings NL, Dart AM, Du XJ. Standardizing a simpler, more sensitive and accurate tail bleeding assay in mice. *World J Exp Med* 2012;2:30-6.
  21. Wang X, Cheng Q, Xu L, Feuerstein GZ, Hsu MY, Smith PL, *et al*. Effects of factor IX or factor XI deficiency on ferric chloride-induced carotid artery occlusion in mice. *J Thromb Haemost* 2005;3:695-702.
  22. Gailani D, Cheng Q, Ivanov IS. Murine models in the evaluation of heparan sulfate-based anticoagulants. *Methods Mol Biol* 2015;1229:483-96.
  23. Cinat ME, Wallace WC, Nastanski F, West J, Sloan S, Ocariz J, *et al*. Improved survival following massive transfusion in patients who have undergone trauma. *Arch Surg* 1999;134:964-8.
  24. Sandhyarani G, Praveen KK. Haemostatic effect of aqueous extract of *Euphorbia nivulia* Buch-Ham. *J Sci* 2014;4:263-6.
  25. Kozen BG, Kircher SJ, Henao J, Godinez FS, Johnson AS. An alternative hemostatic dressing: Comparison of CELOX, HemCon, and QuikClot. *Acad Emerg Med* 2008;15:74-81.
  26. Wedmore I, McManus JG, Pusateri AE, Holcomb JB. A special report on the chitosan-based hemostatic dressing: Experience in current combat operations. *J Trauma* 2006;60:655-8.
  27. Hennekens CH, Buring JE, Sandercock P, Collins R, Peto R. Aspirin and other antiplatelet agents in the secondary and primary prevention of cardiovascular disease. *Circulation* 1989;80:749-56.
  28. Hallas J, Dall M, Andries A, Andersen BS, Aalykke C, Hansen JM, *et al*. Use of single and combined antithrombotic therapy and risk of serious upper gastrointestinal bleeding: Population based case-control study. *BMJ* 2006;333:726.
  29. Bae DK, Park D, Lee SH, Yang G, Yang YH, Kim TK, *et al*. Different antiulcer activities of pantoprazole in stress, alcohol and pylorus ligation-induced ulcer models. *Lab Anim Res* 2011;27:47-52.
  30. Arollado EC, Peñaa IG, Dahiliga VR. Platelet augmentation activity of selected Philippine plants. *Int J Pharm Phytopharmacol Res* 2013;3:121-3.
  31. Patil S, Shetty S, Bhide R, Narayanan S. Evaluation of platelet augmentation activity of *Carica papaya* leaf aqueous extract in rats. *J Pharmacog Phytochem* 2013;1:57-60.
  32. Gray E, Hogwood J, Mulloy B. The anticoagulant and antithrombotic mechanisms of heparin. *Handb Exp Pharmacol* 2012;207:43-61.
  33. Page C. Heparin and related drugs: Beyond anticoagulant activity. *ISRN Pharmacol* 2013;2013:910743.
  34. Vaisakh MN, Pandey A. The invasive weed with healing properties: A review On *Chromolaena odorata*. *Int J Pharma Sci Res* 2012;3:80-3.