

Protective Effect of *Ferulago angulata* (Schltdl.) Boiss. Hydroalcoholic Extract against Acetic Acid-induced Colitis in Rat: Role of Pro-inflammatory Cytokines

Fatemeh Farzaei[#], Fatemeh Heydarpour^{1#}, Mohammad Hosein Farzaei, Zahra Minush Siavash Haghighi², Zahra Abbasabadi, Ehsan Sadeghi¹

Pharmaceutical Sciences Research Center, Kermanshah University of Medical Sciences, ¹Research Center for Environmental Determinants of Health, School of Public Health, Kermanshah University of Medical Sciences, ²Department of Pathology, Faculty of Veterinary Medicine, Razi University, Kermanshah, Iran

[#]These authors have contributed equally to this work

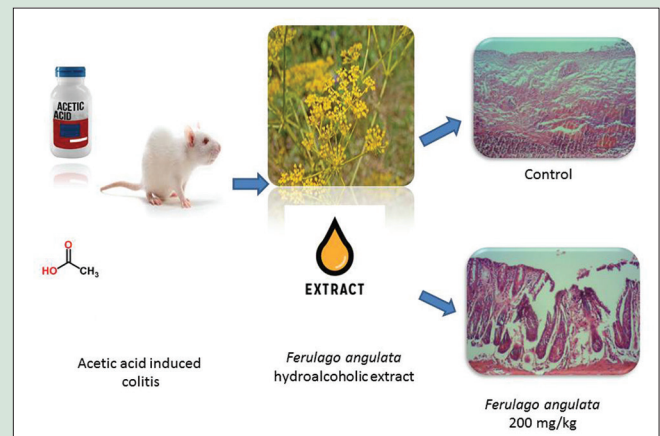
ABSTRACT

Background: Ulcerative colitis (UC) is a chronic recurrent inflammatory disease with unknown etiology. *Ferulago angulata* (Schltdl.) Boiss. has been proposed as an efficacious treatment for gastrointestinal ulcers and UC in the traditional Persian medicine. **Objective:** In the present study, we investigated the possible protective effect of *F. angulata* (Schltdl.) Boiss. hydroalcoholic extract (FAE) against acetic acid-induced UC in rats. **Materials and Methods:** The aerial parts of FAE (50, 100, and 200 mg/kg) were administered orally after acetic acid induced-inflammatory bowel disease. On the 3rd day, animals were euthanized by an overdose of ether inhalation and the abdomen was rapidly dissected for macroscopic, histological, and biochemical (tumor necrosis factor [TNF]- α , interleukin-1 β [IL-1 β]) analyses. **Results:** All doses of *F. angulata* (Schltdl.) Boiss. extract ameliorated acetic acid-induced macroscopic and microscopic scores, except for 50 mg/kg. Furthermore, our observations were accompanied by a significant ($P < 0.05$) suppression in the elevated amount of IL-1 β and TNF- α . **Conclusion:** These findings demonstrated the beneficial effect of hydroalcoholic extract of *F. angulata* (Schltdl.) Boiss. in acetic acid-induced ulcerative lesions via anti-inflammatory, immunomodulatory, and mucosal healing properties. *F. angulata* (Schltdl.) Boiss. possesses promising protective function on colitis.

Key words: *Ferulago angulata* (Schltdl.) Boiss, herbal medicine, inflammatory bowel disease, inflammatory cytokines, medicinal plant, traditional medicine

SUMMARY

- Ulcerative colitis (UC) is a chronic inflammatory disease. *Ferulago angulata* is proposed as an effective treatment for gastrointestinal injuries. In this study, the beneficial effect of this plant was evaluated by acetic acid-induced colitis in rats. All doses of hydroalcoholic extract of *F. angulata* except 50 mg/kg significantly improved macroscopic and microscopic scores. These findings showed that *F. angulata* can be considered as a complementary treatment for suppressing UC symptoms.



Abbreviations Used: IBD: Inflammatory bowel disease; UC: Ulcerative colitis; CD: Crohn's disease; TNF- α : Tumor necrosis factor- α ; IL-1 β : Interleukin-1 β ; PMN: Polymorphonuclear; NO: Nitric oxide; FAE: *Ferulago angulata* (Schltdl.) Boiss. hydroalcoholic extract; COX: Cyclooxygenase.

Correspondence:

Dr. Mohammad Hosein Farzaei,
Pharmaceutical Sciences Research Center,
Kermanshah University of Medical Sciences,
Kermanshah 6734667149, Iran.
E-mail: mh.farzaei@gmail.com and mh_farzaei@kums.ac.ir

DOI: 10.4103/pr.pr_9_18

Access this article online

Website: www.phcogres.com

Quick Response Code:



INTRODUCTION

Inflammatory bowel disease (IBD) is a chronic, life-long, recurrent disorder with disruption of the gut wall caused by leukocyte infiltration and excessive inflammatory mediator generation. Ulcerative colitis (UC) and Crohn's disease are two subcategories of IBD.^[1] Dysregulation of the activated innate immune responses as well as oxidant/antioxidant imbalance well known as cell toxic response, abnormal changes in the intestinal microflora, and irregularity of inflammatory agents are the most important constituents involved in the etiology of IBD. UC was first described in Europe during the 19th century by Dr. Burrill B. Crohn.^[2,3] UC mainly affects the colon and leads to mucosal layer lesions with extensive colonic epithelium damage without granulomas by biopsy. Thus, repetitive relapses and remissions can gradually cause

epithelial dysplasia and ultimately may progress to invasive cancer.^[4] It afflicts about 1–2 million people in the United States and has a growing prevalence, especially in modern countries.^[5,6] The exact cause of UC

This is an open access journal, and articles are distributed under the terms of the Creative Commons Attribution-NonCommercial-ShareAlike 4.0 License, which allows others to remix, tweak, and build upon the work non-commercially, as long as appropriate credit is given and the new creations are licensed under the identical terms.

For reprints contact: reprints@medknow.com

Cite this article as: Farzaei F, Heydarpour F, Farzaei MH, Haghighi ZM, Abbasabadi Z, Sadeghi E. Protective effect of *Ferulago angulata* (Schltdl.) Boiss. hydroalcoholic extract against acetic acid-induced colitis in rat: Role of pro-inflammatory cytokines. Phcog Res 2018;10:391-6.

remains undetermined; however, genetic predisposition and heredity as well as environmental influences, as well as environmental influences as seen in diet, age, time, geographic region differences, and stress, are thought to be important in the pathogenesis of the disease.^[6-9]

TNF- α and interleukin-1 β (IL-1 β) have been implicated as mediators of the inflammatory cascades produced by monocytes and considered as therapeutic targets in the management of IBD due to their crucial role in the signaling pathway.^[1,7,8] Anti-inflammatory drugs such as glucocorticoids and 5-aminosalicylic acid (5-ASA) have been used for treating IBD; however, researchers have been encouraged to examine alternative traditional remedies and medicinal plants due to the interaction of chemical drugs and high rate of side effects as well as disease recurrence. Herbal medicine and natural compounds are one of the reliable areas used for the management of IBD in Iranian traditional medicine sources.^[9,10] A larger number of these plants and their isolated constituents have shown beneficial therapeutic effects, including antioxidant, anti-inflammatory, anti-cancer, anti-microbial, and immunomodulatory effects.^[11,12]

Ferulago angulata (Schltdl.) Boiss. known as Chavir in Persian belonged to *Apiaceae* family is found in high altitude areas of several Asian countries such as Iran, Iraq, and Turkey and has 35 plant species in the world.^[13,14] It is an annual plant with small flowers and yellow fruits grown in the Mediterranean flora and west of Iran (Kermanshah, Ilam, Lorestan, and Kurdistan provinces).^[15] Chavir has been used as an additive in different foods for the preservation of oils. It has demonstrated antioxidant activity as well as anti-inflammatory and antimicrobial properties against *Escherichia coli*, *Pseudomonas aeruginosa*, and *Salmonella typhi*.^[16] It has also been used as sedative, tonic, aphrodisiac properties and a remedy for chronic ulcers, snakebites, headache, and digestive pains such as dyspepsia.^[17] A wide range of phytochemical ingredients were isolated from the extract such as ferulagone, β -hydroxy-13-epi-manoyl oxide, α -pinene, 2,5-dimethoxy-p-cymene, p-cymene, methyl carvacrol, transchrysanthenyl acetate, γ -terpinene (Z)- β -ocimene, α -pinene, myrcene, (Z)- β -ocimene, terpinolene, 2,4,5 trimethylbenzaldehyde, and α -phellandrene.^[18-20] The present study was conducted to investigate the efficacy of the hydroalcoholic extract of *F. angulata* in the experimental model of colitis.

MATERIALS AND METHODS

Material plant

F. angulata was gathered from Dalahoo Mountains in Kermanshah province, West of Iran, with voucher herbarium specimen (No: 580). Afterward, it was air-dried in shade for 1 week and the hydroalcoholic extract was prepared. Fifty grams of powdered herb was solved in 200 ml of equal volume (1:1) of water and methanol for 72 h at 15°C–20°C. The extract was filtered and placed in a vacuumed rotary evaporator solvent.^[21] The reagents and chemical materials for analysis were purchased from Merck (Germany), and rat-specific TNF- α and IL-1 β enzyme-linked immunosorbent assay (ELISA) kits from Bender Med Systems GmbH (Vienna, Austria) were used in this study.

Animal models

Sixty male Wistar-albino rats weighing (150–200 g) were accommodated under standard laboratory conditions of temperature (20°C–25°C), 12-h light/dark cycle, and relative humidity (55% \pm 10%), enough food attainment (standard pellet), and water *ad libitum*. Ethical rules for the investigation on animals were observed carefully, and the experimental protocol was accepted by the Ethical Committee of Kermanshah University of Medical Sciences (KUMS).

Induction of colitis and treatments

Acetic acid-induced colitis is an animal model that mimics some of the acute inflammatory responses seen in UC that first described by MacPherson. Induction of colitis was done according to the Kojima *et al.* method.^[22] It is a classical and simple experimental model of human IBD. According to Farzaei *et al.* (2015), rats were fasted 24 h and were anesthetized with intraperitoneal injection of ketamine (10 mg/kg) with the right-side position. In the following, 1 ml of acetic acid (4% v/v in 0.9% saline) was instilled through rectum via a rubber cannula (8 cm long). Afterward, rats were positioned in supine Trendelenburg position for the prevention of acetic acid leakage. Sulfasalazine used as a reference drug by gavage to the rats.^[23]

Experimental design

Rats were randomly selected from six groups of ten per each. Colitis was induced by installation of acetic acid in all groups, except group 1. As discussed above, 1 ml acetic acid 4% (V/V) was slowly infused into the colon of rats. The groups were (1) normal control group underwent the cannulation procedure without instillation of acetic acid; (2) control group received acetic acid intrarectally 1 h after administration of saline intraperitoneally (i.p.); (3) sulfasalazine group (1 mg/kg/day, i.p.); treatment groups received low, medium, and high doses of *F. angulata* hydroalcoholic extract (FAE) diluted in 1 ml normal saline (4) (FAE): FAE-50 which received 50 mg/kg/day of FAE extract; (5) FAE-100 which received 100 mg/kg/day of FAE extract; (6) FAE-200 which received 200 mg/kg/day of FAE 1 h after acetic acid administration. The rats fasted 24 h before any intracolonic studies and *ad libitum* access to water. FAE dissolved in water extract administered orally by gavage. The study period for all these groups was 3 days. Drugs were administered for 2 successive days, starting from day 1; the colitis induction day. On the day 3, animals were euthanized by an overdose of ether inhalation and the abdomen was rapidly dissected.

Macroscopic and microscopic assessment of colonic damage

Colons were opened longitudinally along mesenteric border and rinsed with normal saline and observed for macroscopic damage scored as described below. Subsequently, colons were cut into pieces in an ice bath and cleansed gently with normal saline. Afterward, the samples were sliced into two pieces, one piece for histopathology assessment (fixed in 5 ml formalin 10%) and the other for measuring biomarkers that were weighed and maintained in 20°C for 24 h. For microscopical evaluation characteristics, the colonic samples were fixed in 10% formalin in phosphate-buffered saline and then stained with hematoxylin and eosin. Afterward, the specimens were scored by an expert pathologist using a method based on following criteria from Farzaei *et al.* (2014): 0, no damage; 1, focal epithelial edema and necrosis; 2, disperse swelling and necrosis of the villi; 3, necrosis with neutrophil infiltration in submucosa; and 4, widespread necrosis with massive neutrophil infiltration and hemorrhage.^[23]

Macroscopic scoring was performed under a magnifying glass by an independent observer based on criteria: 0, intact epithelium with normal appearance and no damage; 1, localized hyperemia without ulceration; 2, linear ulcer with no significant inflammation; 3, linear ulcer with inflammation at one site; 4, two or more sites of ulcer and inflammation; and 5, two or more sites of ulcer and inflammation extending over 1 cm; 5–8: damage extending more than 2 cm along the length of colon, and the score is enhanced by 1 for each increased centimeter of involvement.^[23]

Biochemical assays

Determination of tumor necrosis factor- α and interleukin-1 β

ELISA kit was used to detect TNF- α and IL-1 β levels in colon tissues. The colon was dissected out and the homogenized in 50-mmol/L ice-cold potassium phosphate buffer (pH 6.0) containing 0.5% of hexadecyltrimethylammonium bromide for the measurement of inflammatory cytokines. Homogenates were centrifuged at 4000 rpm for 20 min at 4°C, and supernatants were separated and kept at -80°C until analysis. Briefly, wells precoated with a monoclonal antibody serving to trap cytokine molecules in homogenated specimen. The measurement of final colored product absorbance was assessed at 450 nm as the primary wavelength and 620 nm as the reference wavelength. TNF- α and IL-1 β levels were expressed as pg/mg protein tissue.^[24]

Statistical analysis

Results are expressed as the mean \pm standard error of the mean. Data were evaluated by SPSS (version 19.0, SPSS Inc., Chicago, IL, USA). One-way ANOVA followed by Kruskal-Wallis test for multiple comparisons of the nonparametric result was used. For analysis of parametric data, one-way ANOVA followed by Newman-Keuls *post hoc* test was performed. A $P < 0.05$ was considered statistically significant.

RESULTS

Macroscopic and microscopic assessment of colonic damage

As can be seen in Figure 1, higher macroscopic scores are seen in the control group. Acetic acid administration exhibited significant inflammatory reaction, ulceration, wall thickening, adhesions, and inflammation in control group (5.21 ± 0.38) in comparison with the normal group. Treatment with sulfasalazine attenuated the macroscopic scores (1.42 ± 0.49) significantly compared with control group. The best

healing activity among plant group belonged to FAE-200 (2.22 ± 0.53) which was significantly different from control [Figure 1].

Microscopic evaluation of the control group showed severe necrosis, mucosal and submucosal, even muscular polymorphonuclear (PMN) leukocytes infiltration, as well as loss of the epithelium. Colon features were normal in the normal group. In the FAE-50 group, severe inflammation, diffuse destruction, and necrosis of crypts, as well as PMN infiltration, were observed [Figure 2]. Although FAE-50 (3.35 ± 0.35) score was less than that of the control group, the difference was not significant. The extract (100 and 200 mg/kg) dose-dependently and significantly reduced the scores compared with control group ($P < 0.05$). Treatment with FAE-100 showed mild inflammation and edema of mucosa beside PMN cell infiltration. The lowest microscopic score was seen in the sulfasalazine group (1.35 ± 0.12) followed by group FAE-200 (1.65 ± 0.18).

The macroscopic and microscopic scores in all FAE groups were significantly less than that of the control group except FAE-50 group [Figure 1].

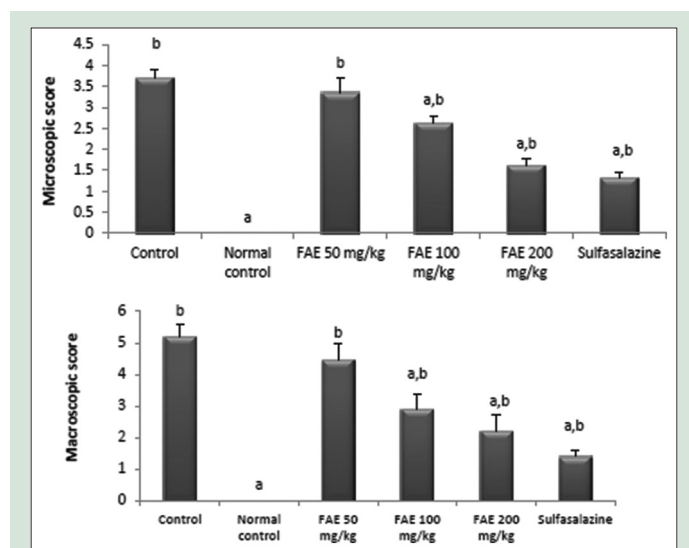


Figure 1: Extent of colonic damage according to macroscopic and microscopic scores in acetic acid-treated rats. Values are mean \pm standard error of the mean. *Ferulago angulata* (Schltdl.) Boiss. hydroalcoholic extract-50: *Ferulago angulata* (Schltdl.) Boiss. hydroalcoholic extract-100: *Ferulago angulata* (Schltdl.) Boiss. hydroalcoholic extract-200: *Ferulago angulata* (Schltdl.) Boiss. hydroalcoholic extract-200 group, mild edematous mucosa with mildly increased number of inflammatory cell was observed. (a) Significantly different from control group ($P < 0.05$). (b) Significantly different from normal control group ($P < 0.05$)

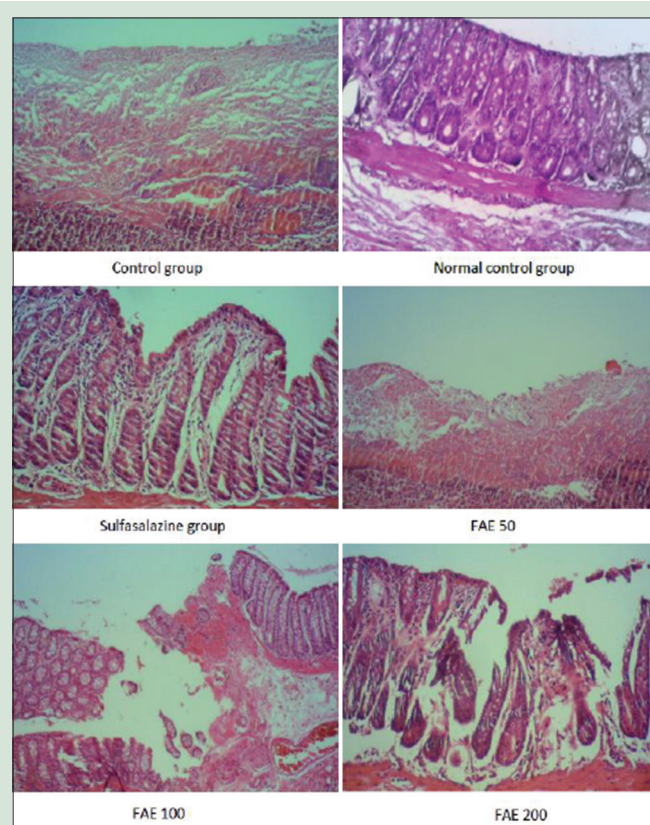


Figure 2: Hematoxylin and eosin-stained sections of the colon tissues obtained from control and experimental groups. Microscopic evaluation of the control group showed loss of mucosal architecture with ulceration and acute inflammatory cell infiltration. In sulfasalazine group, normal large bowel with mild cellular infiltration was observed. In the *Ferulago angulata* (Schltdl.) Boiss. hydroalcoholic extract-50 group, almost diffuse necrosis, severe inflammation of mucosa and submucosa, and neutrophil infiltration were observed. In the *Ferulago angulata* (Schltdl.) Boiss. hydroalcoholic extract-100 group, hyperemia, diffuse mucosal inflammation, and increased number of inflammatory cells were observed. In the *Ferulago angulata* (Schltdl.) Boiss. hydroalcoholic extract-200 group, mild edematous mucosa with mildly increased number of inflammatory cell was observed.

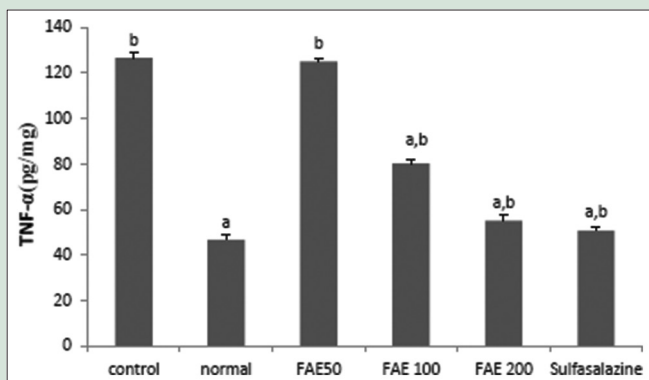


Figure 3: Tumor necrosis factor- α level in the colon. Values are mean \pm standard error of the mean. *Ferulago angulata* (Schltdl.) Boiss. hydroalcoholic extract-50: *Ferulago angulata* (Schltdl.) Boiss. hydroalcoholic extract: *Ferulago angulata* at dose of 50 mg/kg/day, *Ferulago angulata* (Schltdl.) Boiss. hydroalcoholic extract-100: *Ferulago angulata* at dose of 100 mg/kg/day, and *Ferulago angulata* (Schltdl.) Boiss. hydroalcoholic extract-200: *Ferulago angulata* at dose of 200 mg/kg/day. (a) Significantly different from the control group at $P < 0.05$. (b) Significantly different from the normal group at $P < 0.05$

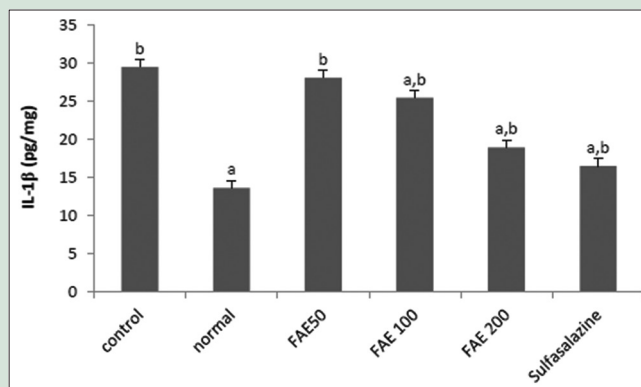


Figure 4: Interleukin-1 β level in the colon. Values are mean \pm standard error of the mean. *Ferulago angulata* (Schltdl.) Boiss. hydroalcoholic extract 50: *Ferulago angulata* at dose of 50 mg/kg/day, *Ferulago angulata* (Schltdl.) Boiss. hydroalcoholic extract 100: *Ferulago angulata* at dose of 100 mg/kg/day, and *Ferulago angulata* (Schltdl.) Boiss. hydroalcoholic extract 200: *Ferulago angulata* at dose of 200 mg/kg/day. (a) Significantly different from the control group at $P < 0.05$. (b) Significantly different from the normal group at $P < 0.05$

Colonic tumor necrosis factor- α

TNF- α level as shown in Figure 3 reduced in a dose-dependent manner in extract-treated groups, except for 50 mg/kg/day in comparison with control ($P < 0.05$). The amount of the TNF- α in the control group was significantly different from the normal group (126.59 ± 2.33). The lowest amount among treated groups belonged to FAE 200 mg/kg (55.01 ± 2.57). Sulfasalazine markedly reduced TNF- α level in colonic mucosa in comparison with the control group ($P < 0.05$) [Figure 3].

Colonic interleukin-1 β levels

IL-1 β in all extract groups was significantly lower than control except 50 mg/kg/day and the lowest amount was belonging to FAE 200 (18.93 ± 1.34) among extract treated groups ($P < 0.05$). IL-1 β amount in normal group was significantly lower than control ($P < 0.05$) [Figure 4].

DISCUSSION

In the current study, the beneficial effects and possible mechanisms of *F. angulata* on acetic acid-induced colitis were studied. Our researches demonstrated the anti-inflammatory effects of FAE against experimental colitis confirmed by histological and macroscopic investigation and its effect was comparable with sulfasalazine group. Administration of hydroalcoholic extract *F. angulata* at 100 and 200 mg/kg attenuates macroscopic and microscopic damages significantly compared to control group ($P < 0.05$) with the best healing activity at 200 mg/kg. According to the histopathologic scoring system, treatment with FAE at 100 and 200 mg/kg/day showed mild neutrophilic infiltration in the lamina propria and mucosal regeneration with undifferentiated epithelial cells. All doses of FAE decreased colonic TNF- α and IL-1 β activities significantly except FAE at 50 mg/kg/day. Sulfasalazine was the first aminosalicyl (11) ate used for maintenance therapy of UC. It consists of sulfapyridine and 5-ASA joined by an azo-bond which is broken by bacteria in the colon. Recent studies have suggested the role of luminal bacteria in IBD. Several researches suggest that anaerobic bacteria and other constituents of the normal luminal microbial flora induce and sustain chronic intestinal inflammation. It has been shown that the concentration of intestinal bacteria in IBD is higher than normal and increases progressively with severity of the disease.^[25]

Cytokine has an important role in gastrointestinal host defense, but their overproduction may cause severe gut inflammation.^[26] As described previously, TNF- α and IL-1 β play an important role in the pathophysiology of intestinal inflammation in IBD disease.^[10] TNF- α is one of the most significant factors participating in the inflammatory process of patients with IBD by inducing the production of other cytokines including adhesion molecules and arachidonic acid metabolites and activation of immune and nonimmune cells.^[27] Bobin-Dubigeon *et al.* demonstrated that antibodies of avian TNF treated IBD in rats.^[28] Bauerle and Henkel suggested that TNF- α and IL-1 activate and translocate NF- κ B into the nucleus.^[29]

Acetic acid-induced colitis is a widely used model that has characteristics partly similar to human colitis. Enhanced vasopermeability, prolonged neutrophils infiltration, enhanced oxidative stress, and increased production of inflammatory mediators are involved in the induction of this animal model in colonic tissue.^[30,31] Elevated colonic levels of TNF- α and IL1 β confirmed severe macroscopic and microscopic damage caused by intrarectal instillation of acetic acid.^[32] The production and release of proinflammatory cytokines (TNF- α , IL-1 β , and IL-6) play a critical role in the pathogenesis of chronic inflammatory diseases. The anti-inflammatory effect of many herbal drugs is now shown to be attributed to their potent suppressive effect of TNF- α , IL-1 β , and/or IL-6 release.^[33] Many medicinal plants have shown beneficial activity on managing IBD through several mechanisms including modulating immune system and proinflammatory cytokines such as cyclooxygenase (Cox), nitric oxide (NO), NF- κ B, and antioxidant and antimicrobial activities.^[11]

F. angulata is a perennial, herbaceous plant that grows in different areas of Iran and is used for the treatment of infectious diseases in traditional medicine and suppressing antibody synthesis.^[34] Phytochemical studies on *Ferulago* species have revealed the presence of coumarins as the most frequent metabolites. Sadeghi *et al.* demonstrated that the majority constituents of the essential oil of *F. angulata* were monoterpene and sesquiterpene hydrocarbons. The main components are cis-ocimene (30.17%), α -pinene (15.4%), trans- β -ocimene (5.7%), γ -terpinene (5.57%), germacrene-D (5.03%), limonene (4.88%), bomyle acetate (4.57%), myrcene (3.62%), camphene (2.41%), noe-allo-ocimene (1.87%), β -phellandrene (1.84%), α -terpinolene (1.7%), bicyclgermacrene (1.29%), and δ -cadinene (1.18%).^[15]

Amirghofran *et al.* demonstrated that aerial parts of *F. angulata* decreased NO secretion with the maximum level of NO ($4.1 \pm 1.6 \mu\text{M}$) after 48 h on lipopolysaccharide-induced inflammation. *F. angulata* also inhibits IL-1 β production significantly.^[35] Mirzapour *et al.* reported that the administration of 400 mg/kg hydroalcoholic extract of *F. angulata* for 2 weeks after brain hypoperfusion ischemia increased the passive avoidance memory and latency time of painful tail reflex significantly ($P < 0.05$).^[36] Azarbani *et al.* demonstrated that aqueous extracts of *F. angulata* flowers exhibited antioxidant activity on DPPH radicals.^[37]

Several studies show that pretreatment with α -pinene significantly decreased levels of TNF- α , intercellular adhesion molecule-1, and macrophage inflammatory protein-2 in the nasal mucosa. In addition, it inhibited the increased activations NF- κ B and caspase-1.^[38]

Rufino *et al.* showed that myrcene has significant anti-inflammatory and anti-catabolic effects in human chondrocytes. Myrcene and limonene inhibited IL-1 β -induced NO production as well as suppression of IL-1 β -induced NF- κ B activation and the expression of inflammatory (iNOS).^[39]

β -Myrcene caused a significant decrease in mucosal malondialdehyde level, an important index of oxidative tissue damage as well as enhancement of superoxide dismutase activity, and increased levels of glutathione peroxidase, glutathione reductase, and total glutathione in gastric tissue. β -Myrcene may be as an anti-ulcer agent and have beneficial role in inhibiting gastric ulcers and increase the gastric mucosal defense factors levels.^[40,41]

CONCLUSION

Pharmacotherapy of UC is principally aimed at inhibiting the production of inflammatory mediators and at modulating the immune system. The current study tried to find an alternative treatment in the management of IBD using herbal medicine in an acetic acid-induced colitis model. This study appears to be a promising approach that may be considered as a complementary treatment of UC. *F. angulata* protected acetic acid-induced intestinal inflammation by reducing inflammatory cytokines.

Acknowledgment

This study was supported by KUMS grant NO. 95530.

Financial support and sponsorship

This study was supported by KUMS.

Conflicts of interest

There are no conflicts of interest.

REFERENCES

- Rahimi R, Nikfar S, Abdollahi M. Induction of clinical response and remission of inflammatory bowel disease by use of herbal medicines: A meta-analysis. *World J Gastroenterol* 2013;19:5738-49.
- Hanauer SB. Inflammatory bowel disease: Epidemiology, pathogenesis, and therapeutic opportunities. *Inflamm Bowel Dis* 2006;12 Suppl 1:S3-9.
- Crohn BB, Ginzburg L, Oppenheimer GD. Regional ileitis: A pathologic and clinical entity. *J Am Med Assoc* 1932;99:1323-9.
- Ullman T, Croog V, Harpaz N, Sachar D, Itzkowitz S. Progression of flat low-grade dysplasia to advanced neoplasia in patients with ulcerative colitis. *Gastroenterology* 2003;125:1311-9.
- Dignass A, Eliakim R, Magro F, Maaser C, Chowers Y, Geboes K, *et al.* Second European evidence-based consensus on the diagnosis and management of ulcerative colitis part 1: Definitions and diagnosis. *J Crohns Colitis* 2012;6:965-90.
- Loftus EV Jr. Clinical epidemiology of inflammatory bowel disease: Incidence, prevalence, and environmental influences. *Gastroenterology* 2004;126:1504-17.

- Wallace KL, Zheng LB, Kanazawa Y, Shih DQ. Immunopathology of inflammatory bowel disease. *World J Gastroenterol* 2014;20:6-21.
- Pedersen J, LaCasse EC, Seidelin JB, Coskun M, Nielsen OH. Inhibitors of apoptosis (IAPs) regulate intestinal immunity and inflammatory bowel disease (IBD) inflammation. *Trends Mol Med* 2014;20:652-65.
- Rahimi R, Shams-Ardekani MR, Abdollahi M. A review of the efficacy of traditional Iranian medicine for inflammatory bowel disease. *World J Gastroenterol* 2010;16:4504-14.
- Rahimi R, Mozaffari S, Abdollahi M. On the use of herbal medicines in management of inflammatory bowel diseases: A systematic review of animal and human studies. *Dig Dis Sci* 2009;54:471-80.
- Dattner AM. From medical herbalism to phytotherapy in dermatology: Back to the future. *Dermatol Ther* 2003;16:106-13.
- Huffman MA. Animal self-medication and ethno-medicine: Exploration and exploitation of the medicinal properties of plants. *Proc Nutr Soc* 2003;62:371-81.
- Valipour P, Heidarian E, Khoshdel A, Gholami-Arjenaki M. Protective effects of hydroalcoholic extract of *Ferulago angulata* against gentamicin-induced nephrotoxicity in rats. *Iran J Kidney Dis* 2016;10:189-96.
- Sadeghi E, Karami F, Etminan A. The effect of *Ferulago angulata* (Schlecht) Boiss essential oil on stabilization of sunflower oil during accelerated storage. *J Food Process Preserv* 2017;41: e12745.
- Sadeghi E, Mahtabani A, Etminan A, Karami F. Stabilization of soybean oil during accelerated storage by essential oil of *Ferulago angulata* Boiss. *J Food Sci Technol* 2016;53:1199-204.
- Rostami F, Ghasemi HA, Taherpour K. Effect of *Scrophularia striata* and *Ferulago angulata*, as alternatives to virginiamycin, on growth performance, intestinal microbial population, immune response, and blood constituents of broiler chickens. *Poult Sci* 2015;94:2202-9.
- Sodeifian G, Ansari K. Optimization of *Ferulago angulata* oil extraction with supercritical carbon dioxide. *J Supercrit Fluids* 2011;57:38-43.
- Ghasempour H, Shirinpour E, Heidari H. The constituents of essential oils of *Ferulago angulata* (Schlecht.) Boiss at two different habitats, Nevakoh and Shahoo, Zagross Mountain, Western Iran. *Iran J Sci Technol Sci* 2007;31:309-12.
- Shahbazi Y, Shavisi N, Karami N, Kakaei S. Chemical composition and *in vitro* antibacterial activity of *Ferulago angulata* (Schlecht.) Boiss essential oil. *Pharma Sci* 2015;21:6.
- Sadeghi E, Mohammadi A, Jamilpanah M, Bashiri M, Bohlouli S. Antimicrobial effects of *Mentha pulegium* essential oil on *Listeria monocytogenes* in Iranian white cheese. *J Food Qual Hazard Control* 2016;3:20-4.
- Mousavi-Ezmareh SF, Mazani M, Heidarian E, Moghadam RA, Rafieian-Kopaei M, Mardanian G, *et al.* The effect of hydroalcoholic extract of *Ferulago angulata* on liver function parameters and antioxidant status in alloxan-induced diabetic rats. *Europ J Med Plants* 2017;20:1-9.
- Kojima R, Hamamoto S, Moriwaki M, Iwadata K, Ohwaki T. The new experimental ulcerative colitis model in rats induced by subserosal injection of acetic acid. *Nihon Yakurigaku Zasshi* 2001;118:123-30.
- Farzaei MH, Ghasemi-Niri SF, Abdolghafari AH, Baeeri M, Khanavi M, Navaei-Nigjeh M, *et al.* Biochemical and histopathological evidence on the beneficial effects of *Tagopogon graminifolius* in TNBS-induced colitis. *Pharm Biol* 2015;53:429-36.
- Ebrahimi F, Esmaily H, Baeeri M, Mohammadirad A, Fallah S, Abdollahi M. Molecular evidences on the benefit of N-acetylcysteine in experimental colitis. *Open Life Sci* 2008;3:135-42.
- Gisbert JP, González-Lama Y, Maté J. 5-aminosalicylates and renal function in inflammatory bowel disease: A systematic review. *Inflamm Bowel Dis* 2007;13:629-38.
- Bossone C, Hosseini JM, Piñero-Carrero V, Shea-Donohue T. Alterations in spontaneous contractions *in vitro* after repeated inflammation of rat distal colon. *Am J Physiol Gastrointest Liver Physiol* 2001;280:G949-57.
- Derkx B, Taminiu J, Radema S, Stronkhorst A, Wortel C, Tytgat G, *et al.* Tumour-necrosis-factor antibody treatment in Crohn's disease. *Lancet* 1993;342:173-4.
- Bobin-Dubigeon C, Collin X, Grimaud N, Robert JM, Le Baut G, Petit JY. Effects of tumour necrosis factor-alpha synthesis inhibitors on rat trinitrobenzene sulphonic acid-induced chronic colitis. *Eur J Pharmacol* 2001;431:103-10.
- Baeuerle PA, Henkel T. Function and activation of NF-kappa B in the immune system. *Annu Rev Immunol* 1994;12:141-79.
- Low D, Nguyen DD, Mizoguchi E. Animal models of ulcerative colitis and their application in drug research. *Drug Des Devel Ther* 2013;7:1341-57.
- Dodda D, Chhajed R, Mishra J. Protective effect of quercetin against acetic acid induced inflammatory bowel disease (IBD) like symptoms in rats: Possible morphological and biochemical alterations. *Pharmacol Rep* 2014;66:169-73.
- Elson CO, Sartor RB, Tennyson GS, Riddell RH. Experimental models of

- inflammatory bowel disease. *Gastroenterology* 1995;109:1344-67.
33. Habtemariam S. Targeting the production of monocytes/macrophages-derived cytokines by anti-inflammatory herbal drugs. *Phytopharmacology* 2013;4:131-48.
 34. Amirghofran Z. Medicinal plants as immunosuppressive agents in traditional Iranian medicine. *Iran J Immunol* 2010;7:65-73.
 35. Amirghofran Z, Malek-Hosseini S, Golmoghaddam H, Kalantar F, Shabani M. Inhibition of nitric oxide production and proinflammatory cytokines by several medicinal plants. *Iran J Immunol* 2011;8:159-69.
 36. Mirzapour S, Rafieirad M, Rouhi L. Hydroalcoholic extract of *Ferulago angulata* improves memory and pain in brain hypoperfusion ischemia in rats. *Jundishapur J Nat Pharm Prod* 2015;10:e17451.
 37. Azarbani F, Saki Z, Zareei A, Mohammadi A. Phenolic contents, antibacterial and antioxidant activities of flower, leaf and stem extracts of *Ferulago angulata* (Schlecht.) Boiss. *Int J Pharm Pharm Sci* 2014;6:123-5.
 38. Nam SY, Chung CK, Seo JH, Rah SY, Kim HM, Jeong HJ. The therapeutic efficacy of α -pinene in an experimental mouse model of allergic rhinitis. *Int Immunopharmacol* 2014;23:273-82.
 39. Rufino AT, Ribeiro M, Sousa C, Judas F, Salgueiro L, Cavaleiro C, et al. Evaluation of the anti-inflammatory, anti-catabolic and pro-anabolic effects of E-caryophyllene, myrcene and limonene in a cell model of osteoarthritis. *Eur J Pharmacol* 2015;750:141-50.
 40. Bonamin F, Moraes TM, Dos Santos RC, Kushima H, Faria FM, Silva MA, et al. The effect of a minor constituent of essential oil from *Citrus aurantium*: The role of β -myrcene in preventing peptic ulcer disease. *Chem Biol Interact* 2014;212:11-9.
 41. Heidari S, Akrami H, Gharaei R, Jalili A, Mahdiuni H, Golezar E. Anti-tumor activity of *Ferulago angulata* Boiss. Extract in gastric cancer cell line via induction of apoptosis. *Iran J Pharm Res* 2014;13:1335-45.