

# Zingiber zerumbet Rhizomes Extract Exhibits Faster Open Wound Healing in Rats

Asmah Hamid, Chong Pek Lian, Nur Hafiza Salleh Hudin, Ahmad Rohi Ghazali, Nurul Farhana Jufri

Program of Biomedical Science, Center of Health and Applied Sciences, Faculty of Health Science, Universiti Kebangsaan Malaysia, Jalan Raja Muda Abdul Aziz, Kuala Lumpur, Malaysia

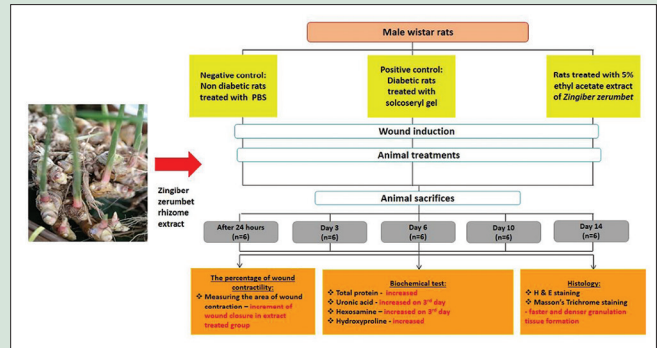
## ABSTRACT

**Background:** *Zingiber zerumbet* rhizome ethyl acetate extract (ZZRE) has the potential to be developed as a wound-healing agent with its profound anti-inflammatory property. **Objective:** This study was conducted to evaluate the wound healing effects of 5% ZZRE on open wound in rats. **Materials and Methods:** Wistar rats ( $n = 90$ ) were divided into three groups, negative control (treated with PBS), positive control (treated with solcoseryl gel), and 5% ethyl acetate extract of *Z. zerumbet*, respectively. Wounds were induced on the rat's dorsal surface on day 0. Measurements of wound closure, total protein, uronic acid, hexosamine, cathepsin B, hydroxyproline, and histological observations were conducted on the wound tissues. **Results:** ZZRE-treated group showed increment in wound closure, protein, and hydroxyproline level. The uronic acid and hexosamine levels of ZZRE-treated wounds significantly increased on the 3<sup>rd</sup> day ( $P < 0.05$ ). Histological observations demonstrated formation of granulation tissue was faster and denser in ZZRE-treated group. **Conclusion:** ZZRE enhances open wound healing in rats and has potential to be developed as a healing agent in the future.

**Key words:** Anti-inflammatory, extract, proteins, rhizomes, wound healing, *Zingiber zerumbet*

## SUMMARY

- Rats treated with *Zingiber zerumbet* rhizomes extract (ZZRE) showed increment in wounds closure, protein levels, and hydroxyproline levels
- The uronic acid and hexosamine levels of ZZRE-treated wounds significantly increased on the third day ( $P < 0.05$ )
- Histological observations demonstrated the formation of granulation tissue was faster and denser in ZZRE-treated group
- ZZRE enhances open wound healing in rats and has potential to be developed as a healing agent in the future.



**Abbreviations Used:** ZZRE: *Zingiber zerumbet* rhizomes extract, PDGF: Platelet-derived growth factor, TGF- $\beta$ : Transforming growth factor-beta, PBS: Phosphate-buffered saline, EDTA: Ethylenediaminetetraacetic acid

## Correspondence:

Dr. Asmah Hamid,  
Assoc. Prof,  
Program of Biomedical Science, Center of Health and Applied Sciences, Faculty of Health Sciences, Universiti Kebangsaan Malaysia, Jalan Raja Muda Abdul Aziz, 50300 Kuala Lumpur, Malaysia.  
E-mail: asmah0901@ukm.edu.my  
DOI: 10.4103/pr.pr\_14\_18

Access this article online

Website: [www.phcogres.com](http://www.phcogres.com)

Quick Response Code:



## INTRODUCTION

Wound is a physical injury resulting in opening or breaking of the skin. Wound healing is essential for the restoration of disrupted anatomical continuity and to repair the disturbed functional status of the skin.<sup>[1]</sup> Wound healing involves a series of cascading cellular and molecular processes for damaged tissue repair, remodeling, and also rapid generation of functional barrier of the skin.<sup>[2]</sup> According to Schultz, wound healing is a physiological process that involves overlapping phases including hemostasis, inflammation, proliferation and remodeling, depending on how the various biological mechanisms are linked.<sup>[3]</sup>

As the blood components accumulate at the site of injury, the platelets come into contact with exposed collagen and other elements of the extracellular matrix. This contact triggers the platelets to release clotting factors, essential growth factors, and cytokines such as platelet-derived growth factor (PDGF) and transforming growth factor-beta (TGF- $\beta$ ). Following hemostasis, the neutrophils enter the wound site and begin the critical task of removing foreign materials, bacteria, and damaged tissue. As the inflammation phase progresses, fixed tissue monocytes differentiated to macrophages that continue releasing more PDGF and TGF- $\beta$  to recruit fibroblasts. Once the wound site is cleared of foreign materials, the migrated fibroblasts will begin the proliferative phase by depositing new

extracellular matrix. Formation of new collagen matrix takes place at the remodeling phase which is the last phase of wound healing.<sup>[4]</sup> Research on wound-healing agents is of interest in the field of modern biomedical science. In fact, traditional medical practitioners worldwide are equipped with valuable information of many lesser known to unknown wild plants for treating wounds and burns, especially in India and China.<sup>[5]</sup> Traditional medicines have been used to treat and heal wounds for thousands of years as they are easily available. However, their wound-healing activities are less proven scientifically.<sup>[6]</sup>

*Zingiberaceae* family plants are widely found in tropical rainforests. In Peninsular Malaysia, about 160 species from 18 genera are found

This is an open access journal, and articles are distributed under the terms of the Creative Commons Attribution-NonCommercial-ShareAlike 4.0 License, which allows others to remix, tweak, and build upon the work non-commercially, as long as appropriate credit is given and the new creations are licensed under the identical terms.

For reprints contact: [reprints@medknow.com](mailto:reprints@medknow.com)

Cite this article as: Hamid A, Lian CP, Salleh Hudin NH, Ghazali AR, Jufri NF. *Zingiber zerumbet* rhizomes extract exhibits faster open wound healing in rats. *Phcog Res* 2018;10:354-60.

and many of them growing naturally as scattered plants at the shaded parts of the lowland or hill slopes.<sup>[7]</sup> *Zingiber zerumbet* (L.) Smith (*Zingiberaceae*), also known as *Lempoyang* in Malaysia, is a wild ginger species commonly used as Malay's cuisine food flavoring and appetizer. This herbal plant has been cultivated for thousands of years as a spice and also for medicinal purposes such as a cure for headaches, swelling, ulcers, loss of appetite, nausea, and menstruation discomfort.<sup>[8]</sup> In Malaysia, the rhizomes have been used to improve appetite, treatment for ulcers, stomachache, diarrhea, worm infestation, analgesics, asthma, rheumatism, and anti-inflammation.<sup>[9,10]</sup>

Ethnopharmacological activities of *Z. zerumbet* have been reported in several studies which include antimicrobial,<sup>[11]</sup> anti-inflammatory,<sup>[12]</sup> antiplatelet, aggregation,<sup>[13]</sup> antihypertensive,<sup>[14]</sup> antinociceptive,<sup>[15]</sup> antiallergic,<sup>[16]</sup> antileukemic,<sup>[17]</sup> hepatoprotective,<sup>[18]</sup> and nephroprotective effects.<sup>[19]</sup> However, the wound-healing activity of *Z. zerumbet* is not studied to date. Therefore, the current study is conducted to evaluate the effect of ethyl acetate extract of *Z. zerumbet* rhizomes on open wound healing in rats through the evaluation of macroscopic and microscopic observations and also biochemical analysis.

## MATERIALS AND METHODS

### Plant materials and extraction

Fresh rhizomes of *Z. zerumbet* were collected from Temerloh, Pahang, Malaysia, and voucher specimen UKMB-29952 was deposited at the herbarium of Universiti Kebangsaan Malaysia (UKM). The specimens were cleaned and ground before air-dried at room temperature. The air-dried rhizomes of *Z. zerumbet* were soaked in n-hexane for 72 h at room temperature. This process was repeated 3 times. The rhizomes then underwent similar process with ethyl acetate. Each crude extract of hexane and ethyl-acetate were filtered and evaporated using rotary evaporator.

### Preparation of 5% ethyl acetate extract of *Zingiber zerumbet*

About 5 g of *Z. zerumbet* rhizome extract (ZZRE) extract was dissolved in 5 mL of dimethyl sulfoxide with ratio of 1:1. The dissolved ZZRE was diluted in 95 mL PBS. The mixture then stirred until homogeneous.

### Experimental animals and study design

Animal handling procedures were reviewed and approved by the Animal Ethics Committee of UKM (FSK/BIOMED/2011/ASMAH/30-November/409-November-2011-May-2013). There were 90 male Wistar rats, weighing 200–250 g used in this study. The rats were obtained from the Laboratory Animal Resource Unit, Faculty of Medicine, UKM, Kuala Lumpur. Food and water were given to animal's *ad libitum*. The rats were acclimatized for a week and randomly divided into three groups of 30 rats each. The Group I consists of negative control given PBS, Group II was positive control treated with solcoseryl gel, and Group III rats were treated with 5% ZZRE. The 5% dose was based on our preliminary study on the extract. Each group was further subdivided into five groups to be sacrificed on the first (24 h after wounding induced), 3<sup>rd</sup>, 6<sup>th</sup>, 10<sup>th</sup>, and 14<sup>th</sup> day, accordingly. Rats were anesthetized to induce six full skin-thickness wounds (6 mm in diameter) using biopsy punch on the dorsal surface on day 0. Treatments were given once daily until the day of sacrifice. The period between treatments was at least 24 h to enable maximum absorption. After the rats were killed, the entire wound was cut for biochemical analysis and macroscopic and histological observation.

### Wound closure measurement

Wound area was measured using 1 mm<sup>2</sup> graph paper on day 0 and the day of killing. The percentage of reduction in wound area was calculated using the equation below:

$$\text{Wound area reduction (\%)} = \left[ 1 - \frac{A_t}{A_0} \right] \times 100$$

Where  $A_t$  is the wound area after time interval  $t$  and  $A_0$  is the wound area at the initial time of experiment, respectively.<sup>[20]</sup>

### Biochemical analysis

#### Total protein

Tissue homogenate was prepared for the determination of total protein content of wound as described by Bradford.<sup>[21]</sup> The tissue supernatant was diluted at dilution factor of 100 with PBS. For 0.1 mL of tissue supernatant, 9.9 mL phosphate buffer was added. Then, 0.1 mL of the mixture was added with 5.0 mL of Bradford reagent before it was read at 595 nm using a spectrophotometer.

#### Uronic acid

Procedures for preparing tissue hydrolysate and estimation of uronic acid content of wound tissue were followed as described by Bitter and Muir.<sup>[22]</sup> Wound tissues were first thawed, cleaned, and dried in the oven at 60°C for 72 h. Every 0.1 g of wound tissues was digested with 1 mg of papain in 10.0 mL of 0.5 M acetate buffer pH 5 containing 0.005 M cysteine and 0.005 M disodium ethylenediaminetetraacetic acid (EDTA) at 65°C for 24 h. Five milliliters of sulfuric acid reagent was placed in a test tube and cooled to 4°C. Then, 1.0 mL of tissue hydrolysate was slowly added into the test tube and mixed. The test tubes were covered with marbles and shaken gently on ice. Mixtures were heated for 10 min in boiling temperature and cooled to room temperature. Next, 0.2 mL of carbazol was added into the mixture. Then the mixture was heated in a boiling water bath for 15 min and cooled to room temperature. The optical density was read at 530 nm.

#### Hexosamine

Tissue homolysate for hexosamine estimation was prepared according to Cheng, with modification.<sup>[23]</sup> Every 20 mg of wound tissue was added with 2.5 mL of 4.0 N of hydrochloric acid. The test tubes were covered with marbles and incubated in boiling temperature for 4 h. Then, distilled water was added until the final volume reached 10.0 mL. Each of 2.0 mL of the filtered hydrolysate is added with 1.0 N of sodium hydroxide to neutralize the pH. Next, the hexosamine content of the hydrolysate was determined as the method described by Isabel.<sup>[24]</sup> Then, 1.0 mL of tissue hydrolysate was mixed with 1.0 mL of freshly prepared acetylacetone reagent. The test tubes were covered with marbles and incubated in boiling temperature for 15 min and cooled to room temperature. Then, 5.0 mL of 95% ethanol was added and mixed, followed by adding 1.0 mL of Ehrlich reagent. Finally, 95% ethanol solution was added to final volume of 10 mL. The optical density was then read at 530 nm.

#### Cathepsin B

Tissue level of cathepsin B was assessed in accordance to Barrett and Kirschke.<sup>[25]</sup> Wound tissues were washed with 0.15 M of sodium chloride. Every 1.0 g of wound tissue were added with 0.5 mL 1% NaCl-2% butan-1-ol 10 mM disodium EDTA. The mixture was then homogenized, and 0.5 mL of tissue supernatant was added with 1.5 mL buffer solution pH 6. The mixture was incubated at 40°C for 5 min. Next, 50.0 µL of substrate solution of 20 mL-Arg-β-naphthylamide

was added to the mixture and left at room temperature for 10 min. Then, 2.0 mL of Brij Mersalil reagent was added to the mixture and left at the room temperature for 10 min. The mixture was read at 520 nm spectroscopically.

### Hydroxyproline

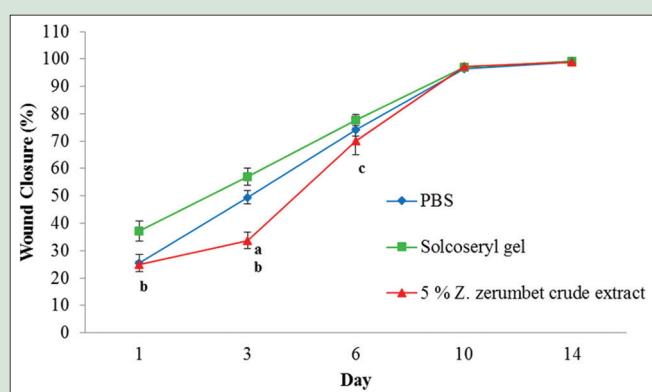
Hydroxyproline level of wound tissue was determined by Stegemann and Stalder method.<sup>[26]</sup> Wound tissues were cleaned and dried in the oven at 60–70°C for 12–18 h. Every 0.1 g of wound tissues was added with 1.0 mL of 6 M hydrochloric acid. The mixture was then homogenized using homogenizer. The tissue homogenate was hydrolyzed in a boiling water bath for 4 h. Next, 1 mL of the supernatant was placed in a test tube and dried using nitrogen gas stream. The dried tissue homogenate was then added with 2.0 mL of buffer solution. Then, 0.1 mL of the mixture was further added with 1.0 mL of buffer solution, followed by 1.0 mL of chloramine T and vortex. After that, 1.0 mL of freshly prepared perchloric acid-aldehyde reagent was added to the mixture and shaken gently until the pink color appeared with no line of transparent (Schlieren) can be seen. The optical density was then read at 550 nm.

### Histological observation

The 0.2 cm × 1.0 cm of wound area was made by excising it from the center of the wound with a sterile, sharp surgical knife. Wound tissue specimens were put in 10% buffered formalin solution, and histological slides were prepared based on the basic processes in the histology slides procedures included dehydration, clearing, tissue infiltration, tissue's embedding, and staining. Wound tissue specimens were stained with hematoxylin and eosin (H and E) and Masson's trichrome following modification of method from Luna.<sup>[27]</sup>

### Statistical analysis

Statistical analysis was conducted using Statistical Package for the Social Sciences 20.0 (IBM Corp., New York, USA) for Windows software. All treatment groups were compared, and the results were analyzed statistically using one-way ANOVA followed by *post hoc* test. Data from statistical analyses are considered statistically significant at  $P < 0.05$  and presented as mean ± standard error of the mean.



**Figure 1:** Percentage of wound closure between groups of treatment on different days. Values presented as mean ± standard error mean. Significant difference ( $P < 0.05$ ) between (a) 5% *Zingiber zerumbet* rhizome ethyl acetate extract with phosphate-buffered saline, (b) 5% *Zingiber zerumbet* rhizome ethyl acetate extract with solcoseryl gel; (c) day of treatment with previous day of treatment. *Z. zerumbet*: *Zingiber zerumbet*; PBS: Phosphate-buffered saline

## RESULTS

### Wound closure measurement

Wound contraction started immediately after wound induction and increased as the time progressed in all groups [Figure 1]. Although a lower contraction percentage was observed in the 5% ZZRE group at initial days, the rate of closure was accelerated between day 6 and day 10, which were comparable to positive control. For the macroscopic observation of wound contractions, wounds of 5% ZZRE-treated group have shown to have comparable closure to both negative and positive control [Figure 2]. Indeed, the redness of the wound margin disappeared at 5% ZZRE-treated group starting from day 3, showing a better healing quality of wounds than the other groups. The open wounds in all treated groups were almost completely closed by day 14.

### Total protein

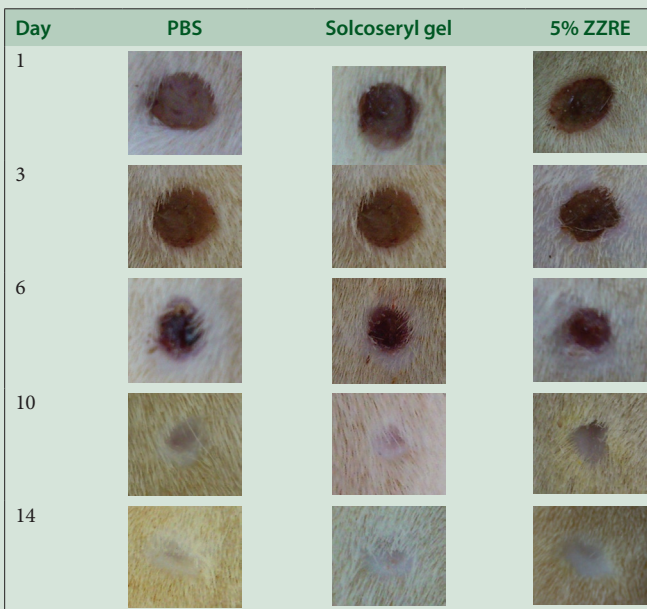
Protein level rapidly increased in 5% ZZRE-treated groups and the level reached to the maximum on day 10 [Figure 3]. The level was significantly higher ( $P < 0.05$ ) on day 6, 10, and 14 compared with control-treated groups.

### Uronic acid

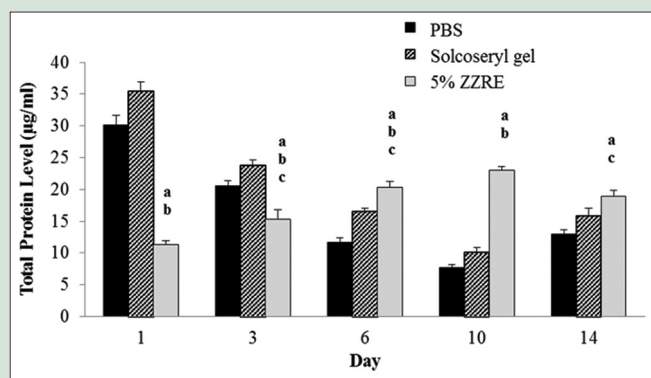
The treated groups showed an increasing pattern of uronic acid from day 1 to day 3 and started decreasing on the following days [Figure 4]. The uronic acid level of 5% ZZRE-treated group was lower significantly ( $P < 0.05$ ) than solcoseryl gel-treated group started from day 1 to day 14.

### Hexosamine

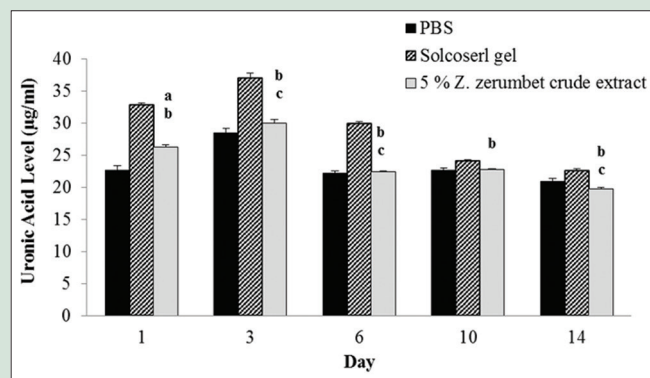
All treated groups displayed the highest level of hexosamine at day 3 and started decreasing from day 6 toward the end of experiment [Figure 5]. The hexosamine level of 5% ZZRE-treated group was lower significantly ( $P < 0.05$ ) as compared to solcoseryl gel-treated group at day 14.



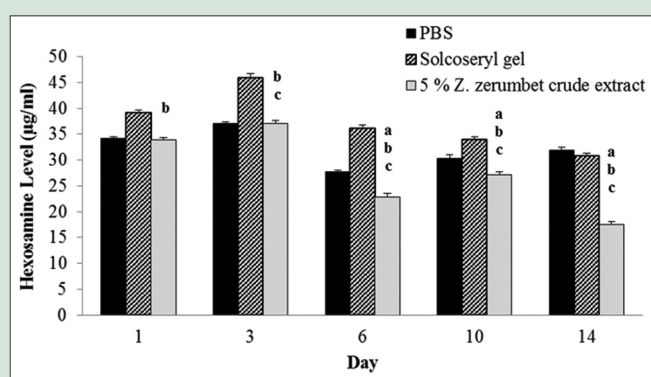
ZZRE: *Zingiber zerumbet* rhizomes extract; PBS: Phosphate-buffered saline  
**Figure 2:** Macroscopic observation of wounds treated with phosphate buffered saline, solcoseryl gel, and 5% *Zingiber zerumbet* rhizome ethyl acetate extract on different days



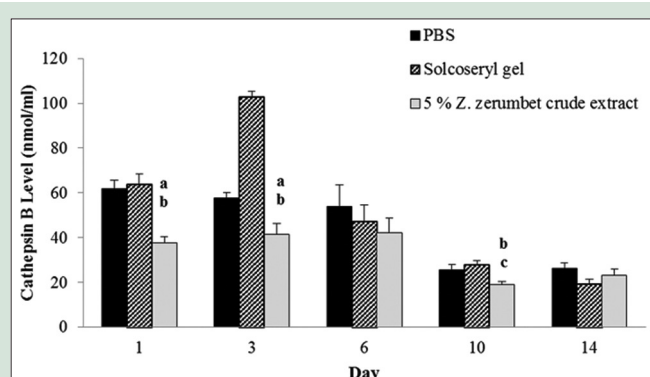
**Figure 3:** Total protein level between groups of treatment on different days. Values presented as mean ± standard error of the mean. Significant difference ( $P < 0.05$ ) between (a) 5% Zingiber zerumbet rhizome ethyl acetate extract with phosphate buffered saline, (b) 5% Zingiber zerumbet rhizome ethyl acetate extract with solcoseryl gel; (c) day of treatment with previous day of treatment. ZZRE: Zingiber zerumbet rhizomes extract; PBS: Phosphate-buffered saline



**Figure 4:** Uronic acid level between groups of treatment on different days. Values presented as mean ± standard error mean. Significant difference ( $P < 0.05$ ) between (a) 5% Zingiber zerumbet rhizome ethyl acetate extract with phosphate buffered saline, (b) 5% Zingiber zerumbet rhizome ethyl acetate extract with solcoseryl gel; (c) day of treatment with previous day of treatment. Z. zerumbet: Zingiber zerumbet; PBS: Phosphate-buffered saline



**Figure 5:** Hexosamine level between groups of treatment on different days. Values presented as mean ± standard error mean. Significant difference ( $P < 0.05$ ) between (a) 5% Zingiber zerumbet rhizome ethyl acetate extract with phosphate buffered saline, (b) 5% Zingiber zerumbet rhizome ethyl acetate extract with solcoseryl gel, (c) day of treatment with previous day of treatment. Z. zerumbet: Zingiber zerumbet; PBS: Phosphate-buffered saline



**Figure 6:** Cathepsin B level between groups of treatment on different days. Values presented as mean ± standard error mean. Significant difference ( $P < 0.05$ ) between (a) 5% Zingiber zerumbet rhizome ethyl acetate extract with phosphate-buffered saline, (b) 5% Zingiber zerumbet rhizome ethyl acetate extract with solcoseryl gel, (c) day of treatment with previous day of treatment. Z. zerumbet: Zingiber zerumbet; PBS: Phosphate-buffered saline

### Cathepsin B

The cathepsin B level for all treated groups was high at the initial phases of wound healing [Figure 6]. However, the 5% ZZRE-treated group displayed lower level of cathepsin B as compared with both negative and positive control groups, significantly at day 1, day 3, and day 10 ( $P < 0.05$ ). Meanwhile, all groups showed similar level of cathepsin B at day 14.

### Hydroxyproline

Hydroxyproline level for 5% ZZRE-treated group displayed the significant lowest hydroxyproline at day 1 ( $P < 0.05$ ) [Figure 7]. However, it rapidly increased at day 3 and reached to the maximum on day 6, which was significantly higher than both negative and positive controls. The hydroxyproline level of 5% ZZRE-treated groups remained the highest at day 14 compared to both control groups, though not significant.

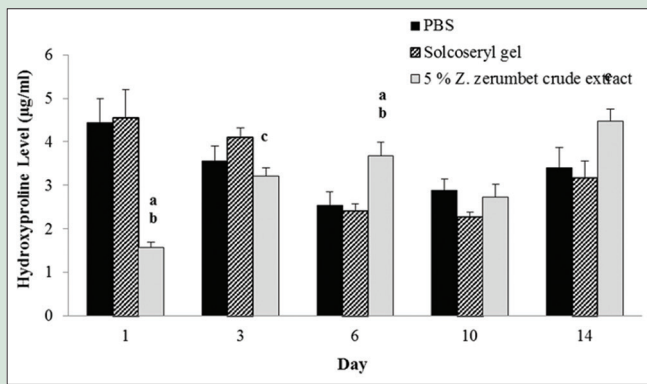
### Histological observations

Histopathological views of wound healing are shown in Figure 8 (H and E staining) and Figure 9 (Masson's trichrome staining).

Wounds treated with 5% ZZRE formed the granulation tissue and collagen at a faster rate, particularly denser than both control groups. Dense revascularization was observed especially in 5% ZZRE-treated group on day 3, despite the inflammatory cells infiltration which was seen in all other groups.

### DISCUSSION

Wound healing is a physiological process that occurs to repair the skin structure and function through several overlapping yet complicated phases of hemostasis, inflammation, proliferation, and remodeling.<sup>[3]</sup> After wound induction, ZZRE-treated group showed significant lower level of total protein compared to other groups. As already known, platelet aggregation and inflammation take place in the wound tissue immediately following injury. According to a study done by Monaco and Lawrence,<sup>[28]</sup> chemical mediators released during platelet degranulation including albumin, fibrinogen, fibronectin, immunoglobulin G, clotting factors, and many growth factors were found to provide direct inflammatory response. Therefore, these supposedly increased the level of protein. As reported by



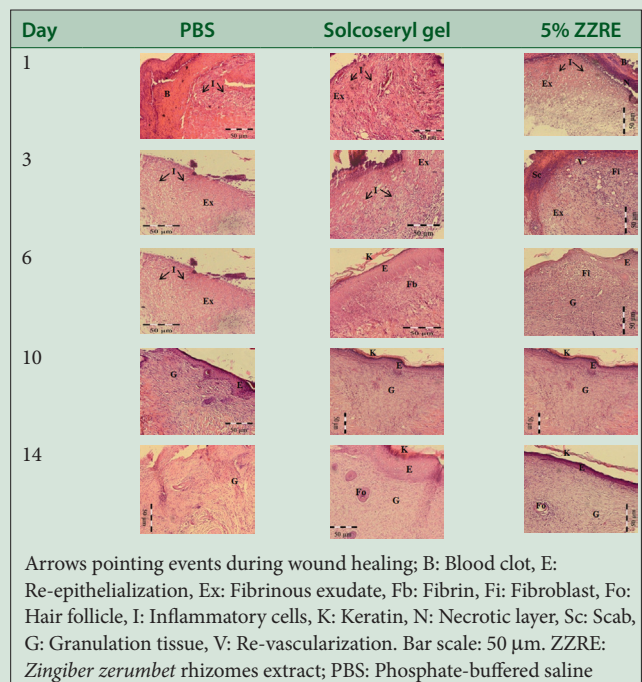
**Figure 7:** Hydroxyproline level between groups of treatment on different days. Values presented as mean  $\pm$  standard error mean. Significant difference ( $P < 0.05$ ) between (a) 5% *Zingiber zerumbet* rhizome ethyl acetate extract with phosphate buffered saline, (b) 5% *Zingiber zerumbet* rhizome ethyl acetate extract with solcoseryl gel, (c) day of treatment with previous day of treatment. *Z. zerumbet*: *Zingiber zerumbet*; PBS: Phosphate-buffered saline

Chien *et al.*, bioactive compounds in *Z. zerumbet* were proven to possess anti-inflammatory effects.<sup>[29]</sup> Hence, the lower protein concentration in ZZRE-treated group might be due to its anti-inflammatory property.

On the other hand, protein level of ZZRE-treated group became significantly higher than the control groups started from day 6 as similarly observed in previous study.<sup>[30]</sup> This might be due to the rapid synthesis of protein that is related to the formation of collagen as it is the major extracellular matrix protein involved in hemostasis. The increased protein level is referred to protein synthesis and cell proliferation that occurs in the wound. Burns *et al.* showed that the protein is required for the proliferation of fibroblasts, formation of new blood vessels, and collagen formation.<sup>[31]</sup> Thus, the increasing level of protein in ZZRE-treated group indicates protein synthesis and cell proliferation which strongly enhance the wound-healing process.

Glycosaminoglycan (GAG) is the first extracellular matrix component being synthesized during wound healing, which forms a template for the deposition of collagen and elastin.<sup>[32]</sup> GAG is a linear polysaccharide with repeated disaccharide unit consisted of uronic acid and hexosamine.<sup>[4,33]</sup> In the present study, the levels of uronic acid and hexosamine for all treatment groups were highest on day 3, indicating highest GAG synthesis. The result was supported by previous studies on normal and diabetic rats in which the levels of uronic acid and hexosamine for each group were highest on day 4 and started decreasing on the following days.<sup>[30,34]</sup> According to Liu *et al.*, GAG is synthesized by fibroblast in wound area which forms a highly hydrated gel-like ground substance.<sup>[35]</sup> The ground substance is a provisional matrix for collagen embedding, subsequently leading to wound closure.

Protease acts importantly in wound healing by degrading base membrane and extracellular matrix to enhance the formation of extracellular scaffold.<sup>[36]</sup> Migration of endothelial cells into the tissue requires degradation of old blood vessels base membrane and also the formation of a strong matrix scaffold to support the growth of new blood vessel.<sup>[37,38]</sup> This process is supported by the functions of proteolytic enzymes such as cathepsin B. The results showed the high levels of cathepsin B at the beginning of wound healing. This is in agreement with research conducted by Tettamanti *et al.*, which proved that the initial high level of cathepsin B is needed for local degradation of the base membrane followed by degradation of the extracellular matrix.<sup>[39]</sup>



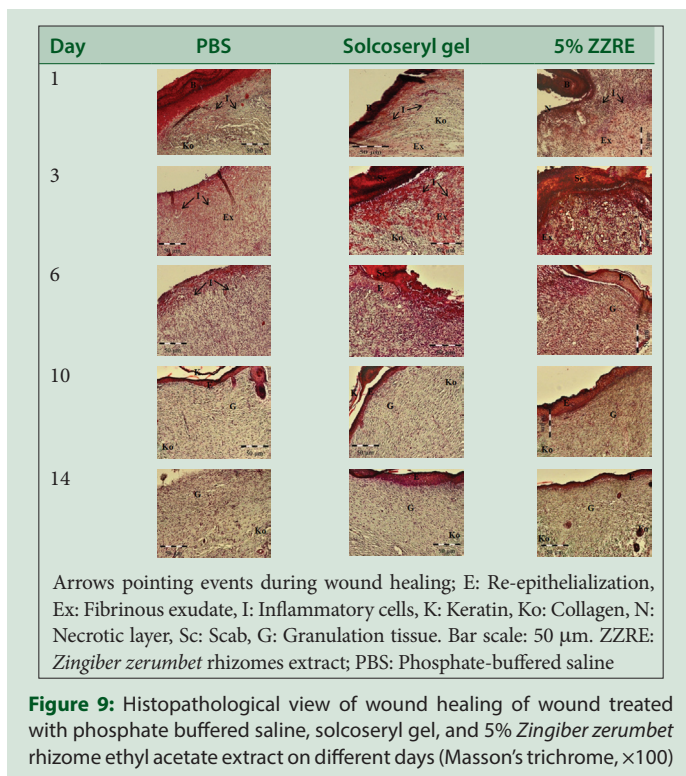
**Figure 8:** Histopathological view of wound healing of wound treated with phosphate buffered saline, solcoseryl gel, and 5% *Zingiber zerumbet* rhizome ethyl acetate extract on different days (H and E,  $\times 100$ )

This is the challenging stage for wound healing in which it promotes cell migration for wound closure.

In this study, the levels of cathepsin B of ZZRE-treated group were significantly lower than control groups in the 1<sup>st</sup> and 3<sup>rd</sup> day. Moulin had reported that acute inflammatory reaction is mediated by macrophages and neutrophils, which in turn synthesize and secrete several growth factors and cytokines.<sup>[40]</sup> Previous studies performed by Grimaldi *et al.*<sup>[41]</sup> found the growth factors released from inflammatory cells will enhance the regulation of cathepsin B expression and activity.<sup>[39]</sup> Therefore, low level of cathepsin B during inflammatory phase is in accordance to the anti-inflammatory activity possessed by *Z. zerumbet* bioactive compound, which may have an influence on inflammatory cells infiltration.

According to Chithra *et al.*, wound contraction depends on deposition and maturation of collagen.<sup>[30]</sup> Collagen is the major extracellular protein found in the wound granulation tissue and its role in wound healing begins immediately after injury and continued for several months. Increasing level of hydroxyproline through 14 days healing phases had been shown in ZZRE-treated group in the study, which is comparable and even higher than solcoseryl gel treatment on day 6. The result is in agreement with Shetty *et al.*, where the increase of hydroxyproline strongly indicated improving wound healing as hydroxyproline reflected collagen content in wounds.<sup>[42]</sup> A rapid increase of collagen content in wound plays important roles in hemostasis and provides the strength and integrity of the wound matrix.<sup>[30]</sup>

The histological observations showed that there is an infiltration of inflammatory cells, formation and maturation of granulation tissue, and also reepithelialization in wounded tissues. Distribution and deposition of collagen were found as shown by Masson's trichrome-stained tissue. Overall, the histological observations showed that wounds treated with ZZRE formed the granulation tissue and collagen at a faster rate and denser than the control groups. The histological observation is parallel with biochemical finding discussed previously.



## CONCLUSION

Treatment of ethyl acetate extract of *Z. zerumbet* rhizome is effective as commercial solcoseryl gel on open wound healing and has the potential to be developed as a wound-healing agent. Further studies to elucidate the bioactive compounds and the mechanisms involved in wound-healing phases shall be conducted in the future.

## Acknowledgement

This study was supported by the Program of Biomedical Science, Faculty of Health Sciences, UKM, and a university grant, GGPM-2011-089.

## Financial support and sponsorship

Nil.

## Conflicts of interest

There are no conflicts of interest.

## REFERENCES

- Singh M, Govindarajan R, Nath V, Rawat AK, Mehrotra S. Antimicrobial, wound healing and antioxidant activity of *Plagiochasma appendiculatum* Lehm. et Lind. J Ethnopharmacol 2006;107:67-72.
- Laplanche AF, Germain L, Auger FA, Moulin V. Mechanisms of wound reepithelialization: Hints from a tissue-engineered reconstructed skin to long-standing questions. FASEB J 2001;15:2377-89.
- Schultz GS. Molecular Regulation of Wound Healing. 2<sup>nd</sup> ed. St Louis: Mosby; 1999.
- Borkow G. Copper's Role in Wound Healing. Biomaterials 2004;1:1-2.
- Kumar B, Vijayakumar M, Govindarajan R, Pushpangadan P. Ethnopharmacological approaches to wound healing-exploring medicinal plants of India. J Ethnopharmacol 2007;114:103-13.
- Sravanthi KC, Sarvani M, Srilakshmi SV. Wound healing herbs-a review. Int J Pharm Technol 2010;2:603-24.
- Saw KL, H. Ibrahim, Khaw SH, Saw LG. Gingers of Peninsular Malaysia and Singapore. Kota Kinabalu, Malaysia: Natural History Publications (Borneo); 1999. P. 136.
- White B. Ginger: An overview. Am Fam Physician 2007;75:1689-91.

- Yob NJ, Jofry SM, Affandi MM, Teh LK, Salleh MZ, Zakaria ZA. *Zingiber zerumbet* (L.) Smith: A review of its ethnomedicinal, chemical, and pharmacological uses. Evid Based Complement Alternat Med 2011;2011:543216.
- Malek SN, Ibrahim H, Hong SL, Lee GS, Chan KS, Yusoff M, et al. Essential oils of *Zingiberottensii* valet and *zerumbet* (L.) Smith Sm. From sabah. Malays J Sci 2005;24:49-58.
- Kader G, Nikkon F, Rashid MA, Yeasmin T. Antimicrobial activities of the rhizome extract of *Zingiber zerumbet* Linn. Asian Pac J Trop Biomed 2011;1:409-12.
- Zakaria ZA, Mohamad AS, Chear CT, Wong YY, Israf DA, Sulaiman MR, et al. Antiinflammatory and antinociceptive activities of *Zingiber zerumbet* methanol extract in experimental model systems. Med Princ Pract 2010;19:287-94.
- Jantan I, Raweh SM, Sirat HM, Jamil S, Mohd Yasin YH, Jalil J, et al. Inhibitory effect of compounds from *Zingiberaceae* species on human platelet aggregation. Phytomedicine 2008;15:306-9.
- Chaung HC, Ho CT, Huang TC. Anti-hypersensitive and anti-inflammatory activities of water extract of *Zingiber zerumbet* (L.) Smith. Food Agric Immunol 2008;19:117-29.
- Sulaiman MR, Tengku Mohamad TA, Shaik Mossadeq WM, Moin S, Yusof M, Mokhtar AF, et al. Antinociceptive activity of the essential oil of *Zingiber zerumbet*. Planta Med 2010;76:107-12.
- Tewtrakul S, Subhadhirasakul S. Anti-allergic activity of some selected plants in the *Zingiberaceae* family. J Ethnopharmacol 2007;109:535-8.
- Abdelwahab SI, Abdul AB, Mohan S, Taha MM, Syam S, Ibrahim MY, et al. Zerumbone induces apoptosis in T-acute lymphoblastic leukemia cells. Leuk Res 2011;35:268-71.
- Hamid A, Budin SB, Mohamed RA, Manaf NA, Yuhana NY, Husain K, et al. Role of oxidative stress in the protective effects of *Zingiber zerumbet* Smith ethyl. Aust J Basic Appl Sci 2011;5:1519-25.
- Abdul Hamid Z, Budin SB, Wen Jie N, Hamid A, Husain K, Mohamed J, et al. Nephroprotective effects of *Zingiber zerumbet* Smith ethyl acetate extract against paracetamol-induced nephrotoxicity and oxidative stress in rats. J Zhejiang Univ Sci B 2012;13:176-85.
- Reddy JS, Rao PR, Reddy MS. Wound healing effects of *Heliotropium indicum*, *Plumbago zeylanicum* and *Acalypha indica* in rats. J Ethnopharmacol 2002;79:249-51.
- Bradford MM. A rapid and sensitive method for the quantitation of microgram quantities of protein utilizing the principle of protein-dye binding. Anal Biochem 1976;72:248-54.
- Bitter T, Muir HM. A modified uronic acid carbazole reaction. Anal Biochem 1962;4:330-4.
- Cheng PT. An improved method for the determination of hexosamine in rat skin. J Invest Dermatol 1968;51:484-90.
- Isabel BV. Post-Harvest Resistance to Fungal Attack in Alfalfa. Canada: University of Manitoba; 1997.
- Barrett AJ, Kirschke H. Cathepsin B, cathepsin H, and cathepsin L. Methods Enzymol 1981;80 Pt C:535-61.
- Stegemann H, Stalder K. Determination of hydroxyproline. Clin Chim Acta 1967;18:267-73.
- Luna L. Manual of Histologic Staining Methods of the AFIP. New York: McGraw-Hill; 1968.
- Monaco JL, Lawrence WT. Acute wound healing an overview. Clin Plast Surg 2003;30:1-2.
- Chien TY, Chen LG, Lee CJ, Lee FY, Wang CC. Anti-inflammatory constituents of *Zingiber zerumbet*. Food Chem 2008;110:584-9.
- Chithra P, Sajithlal GB, Chandrakasan G. Influence of *Aloe vera* on the glycosaminoglycans in the matrix of healing dermal wounds in rats. J Ethnopharmacol 1998;59:179-86.
- Burns JL, Mancoll JS, Phillips LG. Impairments to wound healing. Clin Plast Surg 2003;30:47-56.
- Aljady AM, Kamaruddin MY, Jamal AM, Yassim MY. Biochemical study on the efficacy of Malaysian honey on inflicted wounds: An animal model. Med J Islamic World Acad Sci 2000;13:125-32.
- Rodwell VW, Bender DA, Botham KM, Kenelly PJ, Weil PA. Harper's Illustrated Biochemistry. United States: McGraw Hill Education; 2006:174-83
- Chithra P, Sajithlal GB, Chandrakasan G. Influence of *Aloe vera* on the healing of dermal wounds in diabetic rats. J Ethnopharmacol 1998;59:195-201.
- Liu Y, Cai S, Shu XZ, Shelby J, Prestwich GD. Release of basic fibroblast growth factor from a crosslinked glycosaminoglycan hydrogel promotes wound healing. Wound Repair Regen 2007;15:245-51.
- Badyrak SF. The extracellular matrix as a scaffold for tissue reconstruction. Semin Cell Dev Biol 2002;13:377-83.
- Modlich U, Bicknell R. The Cancer Handbook. London: Nature Publishing Group; 2002.

38. Whelan MC, Senger DR. Collagen I initiates endothelial cell morphogenesis by inducing actin polymerization through suppression of cyclic AMP and protein kinase A. *J Biol Chem* 2003;278:327-34.
39. Tettamanti G, Grimaldi A, Rinaldi L, Arnaboldi F, Congiu T, Valvassori R, *et al.* The multifunctional role of fibroblasts during wound healing in *Hirudo medicinalis* (Annelida, Hirudinea). *Biol Cell* 2004;96:443-55.
40. Moulin V. Growth factors in skin wound healing. *Eur J Cell Biol* 1995;68:1-7.
41. Grimaldi A, Tettamanti G, Rinaldi L, Perletti G, Valvassori R, Eguileor MD. Role of cathepsin B in leech wound healing. *Res Report* 2004;1:38-46.
42. Shetty S, Udupa S, Udupa L. Evaluation of antioxidant and wound healing effects of alcoholic and aqueous extract of *Ocimum sanctum* Linn in rats. *Evid Based Complement Alternat Med* 2008;5:95-101.