

Protective Effect of *Combretum Hypopilinum* Diels: Root Bark Extract against CCl₄-Induced Hepatotoxicity in Wistar Rats

Kokou Idoh, Kossivi Dosseh, Tchazou Kpatcha, Amegnona Agbonon, Messanvi Gbeassor

Department of Physiology/Pharmacology, Faculty of Sciences, University of Lomé, Lomé, Togo

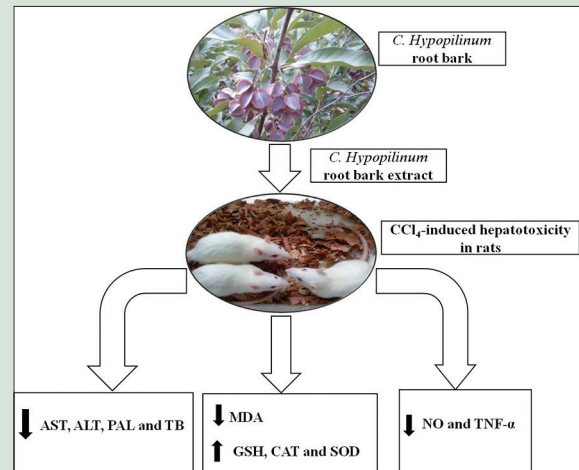
ABSTRACT

Background: *Combretum hypopilinum* is used in Togolese traditional medicine to alleviate various ailments including hepatic disorders. **Objective:** This study evaluates the hepatoprotective activities of crude ethanolic extract of *C. hypopilinum* root bark (CECH) and its possible mechanism(s) of action in Wistar rats. **Materials and methods:** In vitro antioxidant potential was evaluated using DPPH, Ferric-reducing power and hydroxyl radical scavenging assays. Hepatoprotective activity was assessed using CCl₄-induced acute hepatotoxicity in rats. Animals were pretreated orally with different doses of CECH (200 and 400 mg/kg) once daily for 7 consecutive days and were subjected to intraperitoneal single injection of CCl₄ (1 mL/kg). Serum markers of hepatic damage, hepatic endogenous antioxidants, NO, TNF- α and lipid peroxidation contents were measured out. **Results:** The pretreatment with CECH significantly decreased levels of hepatic enzymes ($p < 0.05$, $p < 0.01$, $p < 0.001$) and MDA in pretreated rats ($p < 0.05$, $p < 0.01$). CECH restored the decreased levels of hepatic antioxidants including SOD ($p < 0.01$), CAT ($p < 0.05$ at 400 mg/kg) and GSH ($p < 0.05$ at 400 mg/kg) and significantly inhibited hepatic production of NO ($p < 0.05$, $p < 0.01$), as well as the level of TNF- α ($p < 0.001$) in pretreated rats. Protective effects of CECH were confirmed by histopathological examinations. CECH exhibited antioxidant in vitro and contains also total phenol and flavonoid. **Conclusion:** This study suggests that CECH protected the liver from CCl₄-induced hepatic damage possibly via antioxidant and anti-inflammatory mechanisms.

Key words: *Combretum hypopilinum*, hepatoprotective, oxidative stress, tumor necrosis factor- α .

SUMMARY

- C. hypopilinum* protected the liver against CCl₄-induced hepatotoxicity in rats through antioxidant and anti-inflammatory mechanisms



Abbreviations Used: CECH: Crude ethanolic extract of *combretum hypopilinum* root bark, CCl₄: Carbon tetrachloride, DPPH: 2,2-Diphenyl-1-picrylhydrazyl, AlCl₃: Aluminum chloride, ALT: Alanine aminotransferase, AST: Aspartate aminotransferase, LDH: Lactate dehydrogenase, ALP: Alkaline phosphatase, TC: Total cholesterol, TG: Triglycerides, TB: Total bilirubin, TP: Total protein, MDA: Malondialdehyde, SOD: Superoxide dismutase, CAT: Catalase, GSH: Glutathione, NO: Nitric oxide.

Correspondence:

Prof. Amegnona Agbonon,
Department of Physiology/Pharmacology,
Faculty of Sciences, University of Lomé,
P.O. Box: 1515, Lomé, Togo.
E-mail: aamegnona3@gmail.com
DOI: 10.4103/pr.pr_27_17

Access this article online

Website: www.phcogres.com

Quick Response Code:



INTRODUCTION

The liver represents 2% of total body weight in humans and is the largest solid organ in the body.^[1,2] The liver performs many vital functions including, drugs metabolism and other xenobiotics. Consequently, the liver is prone to xenobiotic-induced injury.^[3] Liver injury can be caused by toxic chemicals, drugs, and virus infiltration from ingestion or infection.^[4,5] However, conventional drugs used in modern pharmacotherapy have shown limited therapeutic benefits and are associated with serious risks sides effects. In the absence of a reliable liver protective drug in the modern system of medicine, natural extracts from medicinal plants considered to be effective and safe are recommended for the treatment of liver disorders.^[6] These plants contain natural antioxidants in the form of tannins, flavonoids, alkaloids, etc. which synergistically provides a protective and beneficial effect to liver cells.^[7,8]

Combretum hypopilinum Diels (Family: Combretaceae; Synonym: *Combretum collinum* Fresen. Subsp. *Hypopilinum* (Diels) Okafa) is a small to medium-sized shrub, with several stems, deciduous, up to

12–17 m tall. It grows in various soils, with semi-arid-to-moderate rainfall conditions. The plant has many uses in Africa, especially in traditional medicine. Infusion of fresh or dried leaves and decoction of roots bark are commonly taken as cholagogic, diuretic, and purgative and also to treat gastrointestinal disorders, including diarrhea, dysentery, and stomach aches.^[9] Decoction of leaves and twigs is taken as a drink, and

This is an open access journal, and articles are distributed under the terms of the Creative Commons Attribution-NonCommercial-ShareAlike 4.0 License, which allows others to remix, tweak, and build upon the work non-commercially, as long as appropriate credit is given and the new creations are licensed under the identical terms.

For reprints contact: reprints@medknow.com

Cite this article as: Idoh K, Dosseh K, Kpatcha T, Agbonon A, Gbeassor M. Protective effect of *Combretum Hypopilinum* diels: Root bark extract against CCl₄-Induced hepatotoxicity in wistar rats. *Phcog Res* 2018;10:325-31.

fresh roots are chewed to treat lung problems such as cough, bronchitis, and tuberculosis and also to treat snake bites and jaundice.^[10] Maceration or decoction of root bark is taken to treat gonorrhoea and infertility in women and men. In addition, the infusion of leaves and roots is taken as a blood tonic.^[11] Few pharmacological and phytochemical studies have been carried out on *C. hypopilinum*. Nevertheless, combretastatins A and B which are stilbenoids and several phenanthrens were isolated from the aerial parts of the plant.^[12] Moreover, a series of amino acids have been isolated from gum exudates, the most important being aspartic acid, glycine, glutamic acid, and alanine.^[13] It has been reported that an aqueous extract of stem bark and root showed antibacterial activity against *Proteus mirabilis* while different leaf extracts showed weak antifungal activities *in vitro*.^[9]

In the Savanna region of Togo, *C. hypopilinum* is known as “Pupiong” (Moba), “Aléblé” (Lamba), or “magic tree” and it is widely used as traditional herbal medicine to alleviate a variety of diseases including headache and jaundice.^[14] Thus, the current study was undertaken to assess the hepatoprotective activity and mechanism(s) of ethanolic root bark extract of *C. hypopilinum* on carbon tetrachloride (CCl₄)-induced acute hepatotoxicity in Wistar rat.

MATERIALS AND METHODS

Plant material and extraction

Roots of *C. hypopilinum* were collected in Dapaong (Far North of Togo, Savanna region) about 650 km from Lomé in March 2014. Botanical authentication was confirmed at the Department of Botany by Prof. Kokou Kwami, University of Lomé, where a voucher specimen of *C. hypopilinum* was deposited in the herbarium (N° TG230314). Roots were cleanly washed with tap water. Root barks were removed and then dried under air conditioning for 7 days. Dried root barks were coarsely reduced into powder. The powder (300 g) was macerated at room temperature with ethanol 95° (3 L) for 72 h under intermittent stirring. The solvent was removed using a rotary vacuum evaporator (Buchi, Switzerland) at 40°C and the crude extract of *C. hypopilinum* (CECH), representing a yield of approximately 10.4% (w/w), was stored at 2°C–8°C until administrated doses preparation, when it was dissolved in sterilized distilled water.

Animals and treatment

Male Wistar rats weighing 150–170 g used in the present study were provided by animals’ facilities of the Laboratory of Physiology and Pharmacology of the Faculty of Sciences, University of Lomé. Animals were housed divided in cages (5 rats per cage) at ambient temperature and humidity with a 12 h day-light cycle, with free access to food and water *ad libitum*. Experimental protocols were based on the World Health Organization guidelines for care and use of laboratory animals, and the use of the animals was approved by the Ethics Committee of the University of Lomé, a branch of the National Ethics Committee for Control and Supervision of Experiments on Animals (N° SBM/UL/14/NS0004).

Chemicals

Silymarin, quercetin, trichloroacetic acid (TCA), sodium chloride, sodium hydrogenphosphate, potassium dihydrogenphosphate, hydrogen peroxide (H₂O₂), glacial acetic acid, potassium ferricyanide (K₃Fe(CN)₆), sodium nitrite (NaNO₂), 5'-dithio-bis-2-nitrobenzoic acid, sodium nitrate, sodium bicarbonate, sodium carbonate (Na₂CO₃), Folin–Ciocalteu’s reagent, sulfanilamide, gallic acid (GA), and aluminum chloride (AlCl₃) were purchased from Sigma–Aldrich (St. Louis, MO, USA). CCl₄ was purchased from BDH Chemicals (Poole, England). Enzyme-linked immunosorbent assay (ELISA) kit for tumor necrosis

factor- α (TNF- α) assay (Rat TNF- α ELISA Kit) was purchased from RayBio Inc., (Norcross, USA).

2,2-Diphenyl-1-picrylhydrazyl radical scavenging assay

Free-radical scavenging activity of CECH was evaluated *in vitro* using the 2,2-diphenyl-1-picrylhydrazyl (DPPH) method described by McCune and Johns.^[15] Briefly, 0.25 mL of a methanol solution of CECH at different concentrations (0–250 μ g/mL) was mixed with 1.5 mL of DPPH (100 μ M). After 15 min of incubation, the change in absorbance with respect to the control (containing DPPH only without sample, expressed as 100% free radicals) was measured at 517 nm. Quercetin was used to generate a standard curve for the 50% inhibition concentration (IC₅₀) determination. The assay was performed in triplicate.

Ferric-reducing antioxidant power assay

The ferric-reducing power of CECH was determined according to previously reported method.^[16] Briefly, to 1 mL of a methanol solution of CECH at different concentrations (0–250 μ g/mL), 2.5 mL of phosphate buffer (0.2 M, pH 6.6) was added followed by addition of 2.5 mL K₃Fe(CN)₆ solution (1%). The reaction mixture was incubated in water bath at 50°C for 15 min. After incubation, TCA (10% w/v, 2.5 mL) was added to the reaction mixture and was centrifuged at 7500 rpm for 15 min. To the aliquot of the upper layer (2.5 mL), distilled water (2.5 mL) and a solution of ferric chloride (0.1%, 0.5 mL) were added. Finally, the absorbance of the reaction mixture was measured at 700 nm. Quercetin was used as a standard. The assay was performed in triplicate.

Hydroxyl radical scavenging assay

Antioxidant effects of *C. hypopilinum* on hydroxyl radical (OH \cdot) was determined according to a previous procedure with slight modification.^[17] Briefly, 1 mL of CECH solution at different concentrations (0–250 μ g/mL) was added to a mixture solution containing 1 mL FeSO₄ (100 mM), 1 mL salicylic acid-ethanol (100 mM), and 1 mL H₂O₂ (200 mM). The resultant mixture was incubated 60 min at 37°C and its absorbance was measured at 510 nm against the blank. The assay was performed in triplicate.

Determination of total flavonoid content

Total flavonoid content in CECH was measured according to colorimetric method using AlCl₃.^[18] CECH or standard (100 μ L, 1 mg/mL) in ethanol was mixed with 0.4 mL of distilled water and 0.03 mL of 5% NaNO₂ solution. After 5 min, 0.02 mL of a 10% AlCl₃ solution was added. To the mixture, 0.02 mL of Na₂CO₃ (1 mol/L) was added, and 5 min later, 0.25 mL of distilled water was added. The solution was well stirred and the absorbance was read at 510 nm. Quercetin was used as a standard to obtain the standard curve (0–500 μ g/mL). Results are expressed as milligram quercetin equivalent per gram of extract (mg Q Eq/g extract).

Determination of total phenol content

Total phenol content was determined by the Folin–Ciocalteu’s method according to Al-Farsi *et al.*^[19] The extract (100 μ L) was mixed with 750 μ L of Folin–Ciocalteu’s reagent (previously diluted 10-fold with distilled water) for 5 min at room temperature. About 750 μ L of aqueous Na₂CO₃ (60 g/L) was added, and the mixture was homogenized and allowed to stand at room temperature for 90 min. After incubation, the absorbance was measured at 725 nm. GA (0–450 μ g/mL) was used as the standard for the calibration curve. Total phenol content was expressed as milligram of GA equivalent per gram of extract (mg GA Eq/g extract).

Hepatoprotective activity of *Combretum hypopilinum* root bark extract

Twenty-five male Wistar rats are used in this study. Animals were randomly divided into 5 groups of 5 each: Group I (control) served as normal control, Group II (CCl₄) served as CCl₄-induced hepatotoxicity model; both Groups I and II were orally given distilled water (10 mL/kg) once daily for 7 consecutive days, Group III (S 100 mg/kg + CCl₄) served as positive control group and was orally given Silymarin (100 mg/kg) once daily for 7 consecutive days, and Groups IV and V (CECH 200 mg/kg + CCl₄ and CECH 400 mg/kg + CCl₄) were orally given CECH, respectively, at 200 or 400 mg/kg once daily for 7 consecutive days. Two hours after last administration of extract or Silymarin, Groups II–V were injected intraperitoneally with a single dose of CCl₄ (1 mL/kg, i. p.) mixed in equal volume of corn oil (v/v), while the normal control group received equal volume of corn oil (1 mL/kg, i. p.). On the 8th day, blood samples were collected from overnight fasted rats through retroorbital sinus puncture for biochemical analysis.^[20] Later, rats were sacrificed by cervical dislocation under mild ether anesthesia and liver was excised and washed in fresh phosphate buffer saline (pH 7.4). Blood was allowed to coagulate and serum was separated by centrifugation at 3000 rpm for 15 min using electric centrifuge (Shimadzu Scientific Corporation Tokyo, Japan). Levels of alanine aminotransferase (ALT), aspartate aminotransferase (AST), lactate dehydrogenase (LDH), alkaline phosphatase (ALP), total cholesterol (TC), triglycerides (TG), total bilirubin (TB), and total protein (TP) were estimated using commercial kits purchased from Human GmbH (Wiesbaden, Germany).

Measurement for hepatic antioxidant markers

Livers were immediately excised, weighed, and homogenized (20%, w/v) in PBS (pH 7.4). The homogenates were then centrifuged as previously. Supernatant was collected and stored at –80°C for further estimations of lipid peroxidation using malondialdehyde (MDA) assay,^[21] superoxide dismutase (SOD) assay,^[22] catalase (CAT) assay,^[23] glutathione (GSH) assay,^[24] and hepatic TP content.^[25]

Measurement for hepatic nitric oxide

Hepatic nitric oxide (NO) content was estimated using Griess reagent according to Fermor *et al.*^[26] Briefly, 500 µL of Griess reagent (Sulfanilamide [1%], *N*-(1-Naphthyl) ethylenediamine [0.1%], and phosphoric acid [2.5%]) were added to 500 µL of liver homogenate. The mixture was homogenized and incubated for 10 min in the darkness. After incubation, the absorbance of the mixture was measured at 570 nm against the blank. Calculations were done after generating a standard curve from NaNO₂ in the same buffer as used for preparation of homogenates. Results are expressed in nmol/mg proteins.

Measurement for hepatic tumor necrosis factor-α

Hepatic TNF-α contents in supernatants were quantified using commercially available rat TNF-α ELISA Kit from RayBio[®] Inc., (Norcross, USA). Measures were performed strictly according to the manufacturer's instructions. The ELISA kits used was specific for the measurement of rats specific TNF-α without cross-reactivity with other cytokines. TNF-α concentration was expressed in ng/g proteins.

Histopathological study

Liver samples were fixed in 10% formalin, dehydrated in graded (50%–100%) alcohol and embedded in paraffin. Thin sections were cut with microtome and stained with hematoxylin and eosin (H and E) stain

for microscopic assessment. Microphotographs of each of the slides were taken with light microscope at ×40 magnification.

Statistical analysis

Results are expressed as mean ± standard error of the mean. Statistical analysis was performed using one-way analysis of variance (ANOVA) followed by Tukey's multiple comparison tests to evaluate significant differences between groups. Results were considered to be significant at $P < 0.05$. All statistical analyses were performed using GraphPad Prism 5 from GraphPad Software, Inc. (California, USA).

RESULTS

In vitro antioxidant activity

The antioxidant potential of CECH was investigated using *in vitro* assays of DPPH radical, ferric-reducing power, and OH[•] scavenging. All antioxidant assays provide support to antioxidant capacity of CECH. In DPPH radical scavenging assay, CECH showed an IC₅₀ of CECH extract: 10,17 ± 2,05 µg/mL while quercetin showed an IC₅₀ of 7.79 ± 1.66 µg/mL. Regarding OH[•] scavenging capacity of CECH, it was noticed to be low to intermediate and increased in a dose-dependent manner [Figure 1a]. Observably, at the same concentration (250 µg/mL), OH[•] scavenging capacity of CECH was 57.68% whereas that of quercetin was 88.56%. Ferric-reducing power of CECH showed a certain degree of ferric-reducing antioxidant potential in a dose-dependent manner. At the same concentration (250 µg/mL), ferric-reducing power of CECH was 69.91%, whereas that of quercetin was 95.15% [Figure 1b]. This study showed that CECH was active scavenger of OH[•]s and active reducer of Fe³⁺. However, its OH[•] scavenging and ferric-reducing potentials are inferior to those of quercetin.

Total phenol and total flavonoid content

Total phenol and flavonoid contents were estimated as 583.56 ± 5.95 mg GA Eq/g extract and 76.11 ± 5.97 mg Q Eq/g extract, respectively, showing that CECH contains a nonnegligible amount of polyphenols and flavonoids.

Hepatoprotective activity

Effect of CECH at the dosages of 200 and 400 mg/kg was studied on serum marker enzymes of liver damage, TP s, and TB in CCl₄-intoxicated rats. Compared to control group (Group I), injection of CCl₄ (Group II) induced significant increase in serum markers of liver injury including

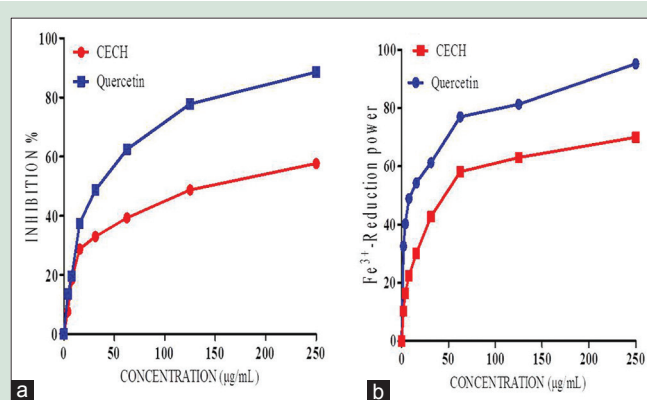


Figure 1: Ferric-reducing power and hydroxyl radical scavenging assays of various concentrations of CECH (a): OH[•]-scavenging capacity and (b): ferric-reducing antioxidant power. CECH: Crude extract of *Combretum hypopilinum*; OH[•]: Hydroxyl radical

transaminases ($P < 0.001$), ALP ($P < 0.001$), and TB ($P < 0.001$). However, pretreatment with *C. hypopilinum* root bark extract has considerably reduced serum concentrations of livers injury markers [Table 1]. Effect of CECH on CCl_4 -induced acute hepatitis is significant at 400 mg/kg ($P < 0.001$) for AST. ALT concentrations also dropped down significantly at 400 mg/kg ($P < 0.05$), while those of ALP and TB began to fall from 200 mg/kg ($P < 0.001$, $P < 0.01$) to 400 mg/kg ($P < 0.001$, $P < 0.01$). LDH levels also decreased but not significantly ($P > 0.05$) as compare to Group II. The same trend is observed in TPs contents where a nonsignificant ($P > 0.05$) increase induced by the extract is observed. Silymarin-pretreated animals also showed significant ($P < 0.001$, $P < 0.01$, $P < 0.05$) protection against CCl_4 -induced liver damage through the above-mentioned markers [Table 1]. The assayed results of serum TG and TC levels are shown in Table 2. It can be seen that CCl_4 induced a systemic accumulation of TG and TC in CCl_4 -injected rats as compare to control rats (Group I). Observably, there is a significant difference in serum levels of TG and TC between control and CCl_4 -injected groups ($P < 0.05$). However, extract of *C. hypopilinum* reduced serum levels of TG and TC in pretreated animals. This diminution was significant at 400 mg/kg ($P < 0.01$) as for TC and at 200 and 400 mg/kg ($P < 0.01$) as for TG.

Histopathological study

H and E-stained sections of liver are shown in Figure 2. Normal liver lobular architecture and cell structure were shown in control group (A). While hepatic tissue of CCl_4 -induced hepatotoxicity model rats showed

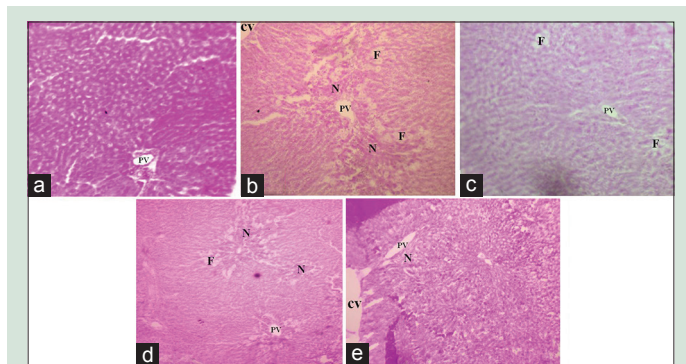


Figure 2: Effects of CECH on histopathological changes. Histological examination was performed under a light microscope ($\times 40$) with hematoxylin and eosin staining. (a) Healthy liver showing normal structure of hepatic cells. (b) Showing massive fatty changes, necrosis, and ballooning degeneration. (c) Liver section after administration of 100 mg/kg of silymarin. (d) Liver section after administration of 200 mg/kg of CECH. (e) Liver section after administration of 400 mg/kg of CECH. N: Necrosis; F: Fatty acid accumulation; PV: Portal vein; CV: Central vein; CECH: Crude extract of *Combretum hypopilinum*

apparent morphological changes including large areas of extensive cell necrosis with loss of hepatocyte architecture (B). However, pretreatment with CECH decreased the injured area and necrotic cells (D and E).

Effects of crude extract of *Combretum hypopilinum* on hepatic antioxidants and malondialdehyde contents

Effects of different treatments on hepatic contents of GSH, SOD, and CAT are shown in Table 3. Results showed clearly that activities of antioxidant enzymes (CAT and SOD) and GSH content significantly ($P < 0.001$, $P < 0.01$) decreased in CCl_4 -induced hepatotoxicity model group (Group II) as compare to control group (Group I). However, pretreatment with CECH (Groups IV and V), for 7 consecutive days, induced significant increase in hepatic CAT and SOD as well as hepatic GSH content. Thus, SOD activity significantly increased at 200 and 400 mg/kg ($P < 0.01$) as compare to Group II. CAT content also increased from 65.0 ± 4.6 U/min/mg protein at 200 mg/kg ($P > 0.05$) to 72.6 ± 6.1 U/min/mg protein at 400 mg/kg ($P < 0.05$). GSH content ranges from 4.47 ± 0.12 nmol/mg protein at 200 mg/kg ($P > 0.05$) to 5.84 ± 0.52 nmol/mg protein at 400 mg/kg ($P < 0.05$).

The hepatic tissue of CCl_4 -intoxicated rats (Group II) showed significantly higher level of MDA as compare to nonintoxicated rats ($P < 0.05$). However, pretreatments with CECH reduced

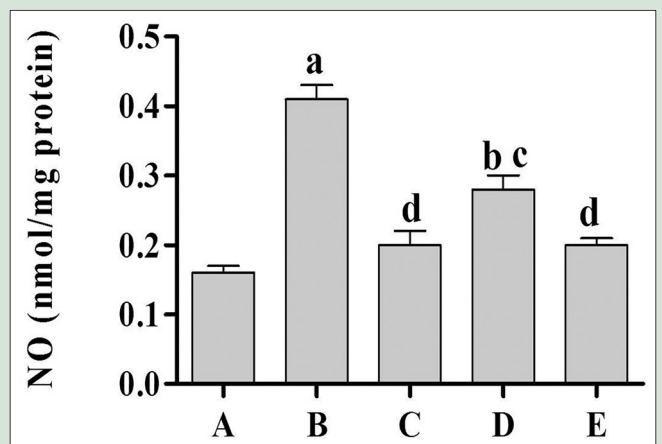


Figure 3: Effect of CECH on hepatic nitric oxide production rats were received oral administration of different doses of CECH once daily for 7 consecutive days and were subsequently subjected to intraperitoneal single injection of CCl_4 (1 mL/kg) and hepatic NO content was measured. Values are expressed as mean \pm standard error of the mean ($n = 5$). ^a $P < 0.001$, ^b $P < 0.05$ as compare to control group (a); ^c $P < 0.05$, ^d $P < 0.01$ as compare to CCl_4 -induced hepatotoxicity model group (b). CECH: Crude extract of *Combretum hypopilinum*; NO: Nitric oxide

Table 1: Effect of *Combretum hypopilinum* on biochemical markers of hepatic injury

Groups	Treatments	AST ^a	ALT ^a	ALP ^a	LDH ^a	TB ^b	TP ^c
I	DW (10 mL/kg)	165.3 \pm 11.80	96.6 \pm 6.8	489.6 \pm 20.8	272.3 \pm 24.7	0.81 \pm 0.1	59.57 \pm 1.0
II	DW (10 mL/kg) + CCl_4	1750 \pm 267.8 ^b	3052 \pm 761.6 ^b	790.3 \pm 64.5 ^b	446.3 \pm 120.6	2.83 \pm 0.6 ^b	48.46 \pm 1.7
III	Silymarin (100 mg/kg) + CCl_4	198.2 \pm 28.24 ^c	125.2 \pm 12.5 ^c	396.6 \pm 20.1 ^c	248.9 \pm 28.5	2.21 \pm 0.3 ^a	63.36 \pm 1.6 ^d
IV	CECH (200 mg/kg) + CCl_4	908.2 \pm 191.9 ^{a,c}	1616 \pm 246.0 ^a	424.4 \pm 24.3 ^c	226.5 \pm 25.6	1.09 \pm 0.1 ^d	58.78 \pm 5.8
V	CECH (400 mg/kg) + CCl_4	661.1 \pm 173.8 ^c	1565 \pm 260.1 ^{a,c}	401.6 \pm 19.2 ^c	303.9 \pm 27.8	1.05 \pm 0.1 ^d	55.68 \pm 4.1

^a $P < 0.05$, ^b $P < 0.001$ as compare to Group I; ^c $P < 0.05$, ^d $P < 0.01$, ^e $P < 0.001$ as compare to Group II. ^aU/L, ^bmg/L, ^cg/L. Rats were received oral administration of different doses of CECH once daily for 7 consecutive days and were subsequently subjected to intraperitoneal single injection of CCl_4 (1 mL/kg) and serum biochemical markers of liver injury were measured. Values are expressed as mean \pm SEM ($n=5$). CECH: Crude extract of *Combretum hypopilinum* root bark; DW: Distilled water; AST: Aspartate aminotransferase; ALT: Alanine aminotransferase; ALP: Alkaline phosphatase; LDH: Lactate dehydrogenase; TB: Total bilirubin; TP: Total proteins; CCl_4 : Carbon tetrachloride; SEM: Standard error of the mean

significantly ($P < 0.05$, $P < 0.01$; at 200 and 400 mg/kg, respectively) MDA contents indicating the effectiveness of CECH against CCl_4 -induced hepatotoxicity [Table 3].

Effects of crude extract of *Combretum hypopilinum* on hepatic nitric oxide and tumor necrosis factor- α production

Results in Figure 3 showed high levels of NO in CCl_4 -induced hepatotoxicity model rats (B) compared to control group (A) ($P < 0.001$). Pretreatment with *C. hypopilinum* root bark extract remarkably inhibited the production of NO in the liver tissue. NO levels in rats pretreated with CECH decreased dose-dependently at the doses of 200 and 400 mg/kg, respectively ($P < 0.05$, $P < 0.01$).

CCl_4 injection in rats increased significantly hepatic TNF- α content as compare to control animals [Figure 4]. Interestingly, pretreatment with *C. hypopilinum* root extract, at the highest dosage (400 mg/kg), significantly inhibited hepatic TNF- α production ($P < 0.001$) as compare to CCl_4 -induced hepatotoxicity model animals [Figure 4].

DISCUSSION

The present study was designed to investigate the protective effect of CECH root bark on CCl_4 -induced hepatotoxicity and its possible mechanism(s) of action. Results showed that CECH exhibited protective activity on CCl_4 -induced liver damage. CECH showed *in vitro* antioxidant potentials and contains total phenolic and flavonoids compounds.

CCl_4 is one of the most widely used toxicants for inducing experimental liver injury in animals, and CCl_4 -induced acute hepatotoxicity is commonly used to investigate the hepatoprotective activity of natural compounds.^[27-30] It has been suggested that CCl_4 causes cellular leakage and a loss of functional integrity of cell membranes in the

liver tissue. Damage to the liver tissues alters their transport function and membrane permeability, leading to leakage of enzymes from the cells.^[31] Therefore, the marked release of AST, ALT, ALP, and LDH into the circulation indicates severe damage to hepatic cell membranes due to CCl_4 intoxication. Hence, administration of CCl_4 in rats could cause a variety of hepatic histological changes, such as hepatocellular necrosis, leukocyte infiltration, portal inflammation, and structural damage.^[32] In the present study, general indicators of CCl_4 -induced hepatotoxicity including AST, ALT, ALP, and LDH activities and serum TB, TP, TG, TC levels and histopathological were evident. However, pretreatment with CECH inhibited liver enzymes leakage into the systemic circulation and attenuated histological changes in rats. These results suggest that CECH significantly suppressed CCl_4 -induced liver injury through the recovery of function and structure of hepatic cells.

CCl_4 requires biotransformation by hepatic microsomal CYP450 to produce degraded metabolite trichloromethyl (CCl_3) free radical which induces oxidative stress and subsequently liver injury.^[27] This product is unstable free radical and exhibits strong affinity for binding to proteins and lipids of the cell membrane or abstracting a hydrogen atom from unsaturated lipid, thereby triggering lipid peroxidation and causing liver damage. Hepatic MDA formation is commonly used as an indicator of

Table 2: Effect of *Combretum hypopilinum* on total cholesterol and triglycerides levels

Groups	Treatments	Total cholesterol (mM)	Triglycerides (mM)
I	DW (10 mL/kg)	0.87±0.02	0.99±0.04
II	DW (10 mL/kg) + CCl_4	1.75±0.45 ^a	1.28±0.09 ^a
III	Silymarin (100 mg/kg) + CCl_4	1.22±0.06	1.12±0.03
IV	CECH (200 mg/kg) + CCl_4	1.06±0.15	0.85±0.05 ^b
V	CECH (400 mg/kg) + CCl_4	0.88±0.14 ^b	0.84±0.05 ^b

^a $P < 0.05$ as compare to Group I, ^b $P < 0.01$ as compare to Group II. Rats were received oral administration of different doses of CECH once daily for 7 consecutive days and were subsequently subjected to intraperitoneal single injection of CCl_4 (1 mL/kg) and serum total cholesterol and triglycerides were measured. Values are expressed as mean±SEM ($n=5$). CECH: Crude extract of *Combretum hypopilinum* root bark; DW: Distilled water; CCl_4 : Carbon tetrachloride; SEM: Standard error of the mean

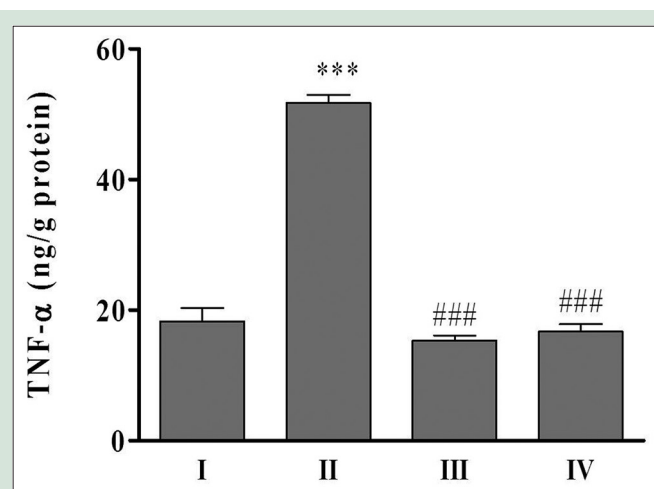


Figure 4: Effect of CECH on hepatic TNF- α content rats were received oral administration of different doses of CECH once daily for 7 consecutive days and were subsequently subjected to intraperitoneal single injection of CCl_4 in equal volume of corn oil (1 mL/kg, v/v) and TNF- α was measured in liver homogenate. (I) Control group, (II) CCl_4 -induced hepatotoxicity model group, (III) S (100 mg/kg) + CCl_4 group, (IV) CECH (400 mg/kg) + CCl_4 group. Values are expressed as mean ± standard error of the mean ($n = 5$). *** $P < 0.001$, versus Group I, ### $P < 0.001$, versus Group II. CECH: Crude extract of *Combretum hypopilinum*; TNF- α : Tumor necrosis factor- α

Table 3: Effect of crude extract of *Combretum hypopilinum* on hepatic antioxidant markers

Groups	Treatments	MDA (nmol/mg proteins)	GSH (nmol/mg proteins)	SOD (U/min/mg proteins)	CAT (U/min/mg proteins)
I	DW (10 mL/kg)	0.96±0.14	5.94±0.56	4.30±0.43	123.3±12.3
II	DW (10 mL/kg) + CCl_4	1.85±0.34 ^a	2.50±0.32 ^b	1.58±0.21 ^c	37.1±8.7 ^c
III	Silymarin (100 mg/kg) + CCl_4	1.25±0.21	3.79±0.28	3.10±0.21 ^d	105.8±8.2 ^f
IV	CECH (200 mg/kg) + CCl_4	0.99±0.19 ^d	4.47±0.12	3.37±0.44e	65.0±4.6 ^c
V	CECH (400 mg/kg) + CCl_4	0.58±0.09 ^e	5.84±0.52 ^d	3.29±0.09e	72.6±6.1 ^{bd}

^a $P < 0.05$, ^b $P < 0.01$, ^c $P < 0.001$ as compared to Group I; ^d $P < 0.05$, ^e $P < 0.01$, ^f $P < 0.001$ as compared to Group II. Rats were received oral administration of different doses of CECH once daily for 7 consecutive days and were subsequently subjected to intraperitoneal single injection of CCl_4 (1 mL/kg) and hepatic MDA, SOD, CAT, and GSH levels were measured. Values are expressed as mean±SEM ($n=5$). CECH: Crude extract of *Combretum hypopilinum*; DW: Distilled water; MDA: Malondialdehyde; SOD: Superoxide dismutase; CAT: Catalase; GSH: Reduced glutathione; CCl_4 : Carbon tetrachloride; SEM: Standard error of the mean

liver tissue damage and increase in hepatic MDA content suggests the enhanced lipid peroxidation, resulting in tissue damage and failure of the antioxidant defense mechanisms to prevent the formation of excessive free radicals.^[33,34] Previous studies reported that natural compounds from plants reduce CCl₄-induced lipid peroxidation in animal models.^[35,36] In the current study, CCl₄ caused an increase in hepatic MDA content in CCl₄-induced hepatotoxicity model group, as compared to the normal group. However, pretreatment with CECH significantly ($P < 0.05$, $P < 0.01$) decreased hepatic level of MDA, suggesting that CECH inhibited lipid peroxidation reaction triggered by CCl₄.

In human organism, cells have a number of mechanisms to defend themselves from the toxic effect of reactive oxygen species (ROS) including free-radical scavengers and chain reaction terminators such as SOD, CAT, and GSH.^[37] SOD removes superoxide radicals by converting them into H₂O₂ which can be rapidly converted into water by CAT and GSH.^[37] Our results showed deep decrease in hepatic SOD, CAT, and GSH contents in CCl₄-induced hepatotoxicity model group, revealing that acute CCl₄-induced oxidative liver injury had already occurred, and these results were in agreement with a previous study.^[38] Interestingly, the CECH pretreatment at the doses of 200 and 400 mg/kg significantly reversed the trend. Pretreatment with CECH markedly elevated hepatic levels of SOD, CAT, and GSH. The present study suggests that CCl₄ increased ROS production in the liver and it was inhibited by the CECH pretreatment. This protective action may arise due to the potent free-radical scavenging activities of CECH. It was clear that CECH protected the liver by means of improving enzymatic and nonenzymatic antioxidant defense system to effectively alleviate the generation of free radicals activated by CCl₄. Furthermore, it has been suggested that natural compounds can act as direct antioxidants through scavenging ROS or inhibiting their formation and also as indirect antioxidants through upregulation of endogenous antioxidant defenses.^[39] Hence, scavenging free radicals with various natural products provides quite important means to protect against CCl₄-induced liver oxidative stress. In the current study, CECH exerted a good scavenging activity against DPPH and OH[•] free radicals. The extract exhibited a dose-dependent activity as a free-radical scavenger, with a dose-dependent manner regarding ferric-reducing antioxidant power assay. CECH contains also total phenol and flavonoid in a nonnegligible proportion. These results suggest that CECH not only upregulated hepatic endogenous antioxidants but also it might possibly act as CCl₄-derived free-radical scavenger.

CCl₄-induced hepatotoxicity is characterized by two subsequent phases: a direct oxidative stress leading to hepatocyte death in the first phase and secondary damage from Kupffer cells. In fact, CCl₄ can cause liver inflammation and activate Kupffer cells. Kupffer cells, once activated, release pro-inflammatory cytokines including TNF- α and other pro-inflammatory cytokines.^[40-43] An early increase in the TNF- α level induces expression of inflammatory mediators, including inducible NO synthase (iNOS) which produces NO. NO could subsequently cause liver damage by producing ROS through a reaction with a superoxide anion.^[44] Furthermore, recent reports demonstrated that iNOS and COX-1 and COX-2 overexpression occurs in the liver of rats with CCl₄-induced acute liver injury.^[45,46] Therefore, anti-inflammatory therapy may ameliorate CCl₄-induced liver damage.

Huang *et al.*^[47] suggested that antrosterol from *Antrodia camphorata* submerged whole broth protects against CCl₄-induced acute liver injury in mice through the decrease of TNF- α levels and NO production. Results from the current study revealed that pretreatment with CECH significantly decreased hepatic contents of NO and TNF- α , suggesting CECH might suppress the inflammatory response through the inhibition of inflammatory cytokines and NO production. Altogether, the above

results suggest that CECH might ameliorate CCl₄-induced liver injury in rats through suppressing the CCl₄-induced inflammatory response as well as elevating rats' antioxidant capacities.

CONCLUSION

The current study demonstrated that CECH protected the liver against CCl₄-induced hepatotoxicity, possibly by scavenging free radicals, improving the endogenous antioxidant system, and inhibiting inflammation response by decreasing NO and pro-inflammatory cytokine TNF- α production.

Acknowledgments

The authors are thankful to Professor Koffi Amegbor and his collaborators for histopathological slide preparation and observation.

Financial support and sponsorship

Nil.

Conflicts of interest

There are no conflicts of interest.

REFERENCES

- Duncan AW, Dorrell C, Grompe M. Stem cells and liver regeneration. *Gastroenterology* 2009;137:466-81.
- Fausto N, Campbell JS. The role of hepatocytes and oval cells in liver regeneration and repopulation. *Mech Dev* 2003;120:117-30.
- Sturgill MG, Lambert GH. Xenobiotic-induced hepatotoxicity: Mechanisms of liver injury and methods of monitoring hepatic function. *Clin Chem* 1997;43:1512-26.
- Lee CP, Shih PH, Hsu CL, Yen GC. Hepatoprotection of tea seed oil (*Camellia oleifera* Abel.) against CCl₄-induced oxidative damage in rats. *Food Chem Toxicol* 2007;45:888-95.
- Mihailović V, Mihailović M, Uskoković A, Arambašić J, Mišić D, Stanković V, *et al.* Hepatoprotective effects of *Gentiana asclepiadea* L. Extracts against carbon tetrachloride induced liver injury in rats. *Food Chem Toxicol* 2013;52:83-90.
- Jaishree V, Badami S. Antioxidant and hepatoprotective effect of swertiamarin from *enicostemma axillare* against D-galactosamine induced acute liver damage in rats. *J Ethnopharmacol* 2010;130:103-6.
- Ajay A, Sairam PK, Seivasta GC. Oxidative stress and antioxidative system in plants. *Curr Sci* 2002;82:1227-38.
- Wolf PL. Biochemical diagnosis of liver disease. *Indian J Clin Biochem* 1999;14:59-90.
- Fyhrquist P, Mwasumbi L, Haeggstrom C, Vuorela H, Hitunen R, Vuorela P. Antifungal activity of selected species of *Terminalia*, *Pteleopsis* and *Combretum* (*Combretaceae*) collected in Tanzania. *Pharm Biol* 2004;42:308-17.
- Eloff J. The antibacterial activity of 27 Southern African members of the *Combretaceae*. *S Afr J Sci* 1999;95:148-52.
- Abreu PM, Martins ES, Kayser O, Bindseil KU, Siems K, Seemann A, *et al.* Antimicrobial, antitumor and antileishmania screening of medicinal plants from Guinea-Bissau. *Phytomedicine* 1999;6:187-95.
- Rogers C, Coombes P. Acidic triterpene glycosides in trichome secretions differentiate subspecies of *Combretum collinum* in South Africa. *Biochem Syst Ecol* 1999;27:321-3.
- Anderson D, Howlett J, McNab C. Amino acid composition of gum exudates from some African *Combretum*, *Terminalia* and *Anogeissus* species. *Phytochemistry*. 1987;26:837-9.
- Adjanohoun EJ, Ahyi AM, Ake AL, Akpagana K, Chibon P, El-Hadji A, *et al.* Contribution aux études ethnobotaniques et floristiques au Togo. In: *Medecine traditionnelle et Pharmacopée*. Paris, France, Agence de Coopération Culturelle et Technique (ACCT); 1986. p. 526-31.
- McCune LM, Johns T. Antioxidant activity in medicinal plants associated with the symptoms of diabetes mellitus used by the indigenous peoples of the North American boreal forest. *J Ethnopharmacol* 2002;82:197-205.
- Yen GC, Chen HY. Antioxidant activity of various tea extracts in relation to their antimutagenicity. *J Agric Food Chem* 1995;43:27-37.
- Sminoff N, Cumbes QJ. Hydroxyl radical scavenging activity of compatible solutes. *Phytochemistry* 1989;28:1057-60.
- Kim DO, Chun OK, Kim YJ, Moon HY, Lee CY. Quantification of polyphenolics and

- their antioxidant capacity in fresh plums. *J Agric Food Chem* 2003;51:6509-15.
19. Al-Farsi M, Alasalvar C, Morris A, Baron M, Shahidi F. Comparison of antioxidant activity, anthocyanins, carotenoids, and phenolics of three native fresh and sun-dried date (*Phoenix dactylifera* L.) varieties grown in Oman. *J Agric Food Chem* 2005;53:7592-9.
 20. Waynforth BH. Injection techniques. In: *Experimental and Surgical Techniques in the Rat*. USA: London/NY; 1980. p. 30-61.
 21. Wilbur KM, Bernheim F, Shapiro OW. Determination of lipid peroxidation. *Arch Biochem Biophys* 1949;24:305-10.
 22. Misra HP, Fridovich I. The role of superoxide anion in the autoxidation of epinephrine and a simple assay for superoxide dismutase. *J Biol Chem* 1972;247:3170-5.
 23. Soon YY, Tan BK. Evaluation of the hypoglycemic and anti-oxidant activities of *Morinda officinalis* in streptozotocin-induced diabetic rats. *Singapore Med J* 2002;43:077-85.
 24. Ellman GL. Tissue sulfhydryl groups. *Arch Biochem Biophys* 1959;82:70-7.
 25. Lowry OH, Rosebrough NJ, Farr AL, Randall RJ. Protein measurement with the folin phenol reagent. *J Biol Chem* 1951;193:265-75.
 26. Fermor B, Weinberg JB, Pisetsky DS, Misukonis MA, Banes AJ, Guilak F, *et al.* The effects of static and intermittent compression on nitric oxide production in articular cartilage explants. *J Orthop Res* 2001;19:729-37.
 27. Brautbar N, Williams J 2nd. Industrial solvents and liver toxicity: Risk assessment, risk factors and mechanisms. *Int J Hyg Environ Health* 2002;205:479-91.
 28. Kujawska M, Ignatowicz E, Murias M, Ewertowska M, Mikolajczyk K, Jodyns-Liebert J, *et al.* Protective effect of red beetroot against carbon tetrachloride- and N-nitrosodiethylamine-induced oxidative stress in rats. *J Agric Food Chem* 2009;57:2570-5.
 29. Sarhadynjad Z, Sharififar F, Pardakhty A, Nematollahi MH, Sattaie-Mokhtari S, Mandegary A, *et al.* Pharmacological safety evaluation of a traditional herbal medicine "Zereshk-e-saghir" and assessment of its hepatoprotective effects on carbon tetrachloride induced hepatic damage in rats. *J Ethnopharmacol* 2016;190:387-95.
 30. Xie Q, Guo FF, Zhou W. Protective effects of cassia seed ethanol extract against carbon tetrachloride-induced liver injury in mice. *Acta Biochim Pol* 2012;59:265-70.
 31. Adesanoye OA, Farombi EO. Hepatoprotective effects of *Vernonia amygdalina* (astereaceae) in rats treated with carbon tetrachloride. *Exp Toxicol Pathol* 2010;62:197-206.
 32. Song SZ, Choi YH, Jin GY, Li GZ, Yan GH. Protective effect of cornuside against carbon tetrachloride-induced acute hepatic injury. *Biosci Biotechnol Biochem* 2011;75:656-61.
 33. Dreissigacker U, Suchy MT, Maassen N, Tsikas D. Human plasma concentrations of malondialdehyde (MDA) and the F2-isoprostane 15(S)-8-iso-PGF (2alpha) may be markedly compromised by hemolysis: Evidence by GC-MS/MS and potential analytical and biological ramifications. *Clin Biochem* 2010;43:159-67.
 34. Krajka-Kuźniak V, Szaefer H, Ignatowicz E, Adamska T, Baer-Dubowska W. Beetroot juice protects against N-nitrosodiethylamine-induced liver injury in rats. *Food Chem Toxicol* 2012;50:2027-33.
 35. Dhanasekaran M, Ignacimuthu S, Agastian P. Potential hepatoprotective activity of ononitol monohydrate isolated from *Cassia tora* L. On carbon tetrachloride induced hepatotoxicity in wistar rats. *Phytomedicine* 2009;16:891-5.
 36. Lee KJ, Choi JH, Hwang YP, Chung YC, Jeong HG. Protective effect of caffeic acid phenethyl ester on tert-butyl hydroperoxide-induced oxidative hepatotoxicity and DNA damage. *Food Chem Toxicol* 2008;46:2445-50.
 37. Yamanaka K, Hasegawa A, Sawamura R, Okada S. Cellular response to oxidative damage in lung induced by the administration of dimethylarsinic acid, a major metabolite of inorganic arsenic, in mice. *Toxicol Appl Pharmacol* 1991;108:205-13.
 38. Sathesh Kumar S, Ravi Kumar B, Krishna Mohan G. Hepatoprotective effect of *Trichosanthes cucumerina* var *cucumerina* L. On carbon tetrachloride induced liver damage in rats. *J Ethnopharmacol* 2009;123:347-50.
 39. Dinkova-Kostova AT, Talalay P. Direct and indirect antioxidant properties of inducers of cytoprotective proteins. *Mol Nutr Food Res* 2008;52 Suppl 1:S128-38.
 40. Brucoleri A, Gallucci R, Germolec DR, Blackshear P, Simeonova P, Thurman RG, *et al.* Induction of early-immediate genes by tumor necrosis factor alpha contribute to liver repair following chemical-induced hepatotoxicity. *Hepatology* 1997;25:133-41.
 41. McCay PB, Lai EK, Poyer JL, DuBose CM, Janzen EG. Oxygen- and carbon-centered free radical formation during carbon tetrachloride metabolism. Observation of lipid radicals *in vivo* and *in vitro*. *J Biol Chem* 1984;259:2135-43.
 42. Edwards MJ, Keller BJ, Kauffman FC, Thurman RG. The involvement of kupffer cells in carbon tetrachloride toxicity. *Toxicol Appl Pharmacol* 1993;119:275-9.
 43. Elsisy AE, Earnest DL, Sipes IG. Vitamin A potentiation of carbon tetrachloride hepatotoxicity: Role of liver macrophages and active oxygen species. *Toxicol Appl Pharmacol* 1993;119:295-301.
 44. Domitrović R, Jakovac H, Milin C, Radosević-Stasić B. Dose- and time-dependent effects of luteolin on carbon tetrachloride-induced hepatotoxicity in mice. *Exp Toxicol Pathol* 2009;61:581-9.
 45. Domitrović R, Jakovac H, Blagojević G. Hepatoprotective activity of berberine is mediated by inhibition of TNF- α , COX-2, and iNOS expression in CCl(4)-intoxicated mice. *Toxicology* 2011;280:33-43.
 46. Deng JS, Chang YC, Wen CL, Liao JC, Hou WC, Amagaya S, *et al.* Hepatoprotective effect of the ethanol extract of *Vitis thunbergii* on carbon tetrachloride-induced acute hepatotoxicity in rats through anti-oxidative activities. *J Ethnopharmacol* 2012;142:795-803.
 47. Huang GJ, Deng JS, Huang SS, Shao YY, Chen CC, Kuo YH. Protective effect of antrosterol from *Antrodia camphorata* submerged whole broth against carbon tetrachloride-induced acute liver injury in mice. *Food Chem* 2012;132:709-16.